Glandular epithelial tissues

- **Some related terms**
- ***Gland:*** Single cell or group of cells, derived from epithelia, secrete substances into ducts, onto a surface, or into the blood.
- ***Glandular Epithelium:*** epithelium of cells specialized to produce secretion. All glands are composed of epithelium.
- ***Myoepithelium:*** specialized squamous epithelial cells with powers of contraction; surround glandular acini and ducts of many glands, contain actin, myosin, cytotokeratin
- **Events on secretory cells**
  1) Differentiate but remain in the lining epithelium
  2) Invaginate into the underlying connective tissue and remain attached to the lining epithelium
  3) Invaginate into the underlying connective tissue but lose their connection to the epithelium.

Classification of glandular epithelium:

- Generally glands classify according to the presence or absence of duct into exocrine and endocrine glands:

Glandular Epithelium

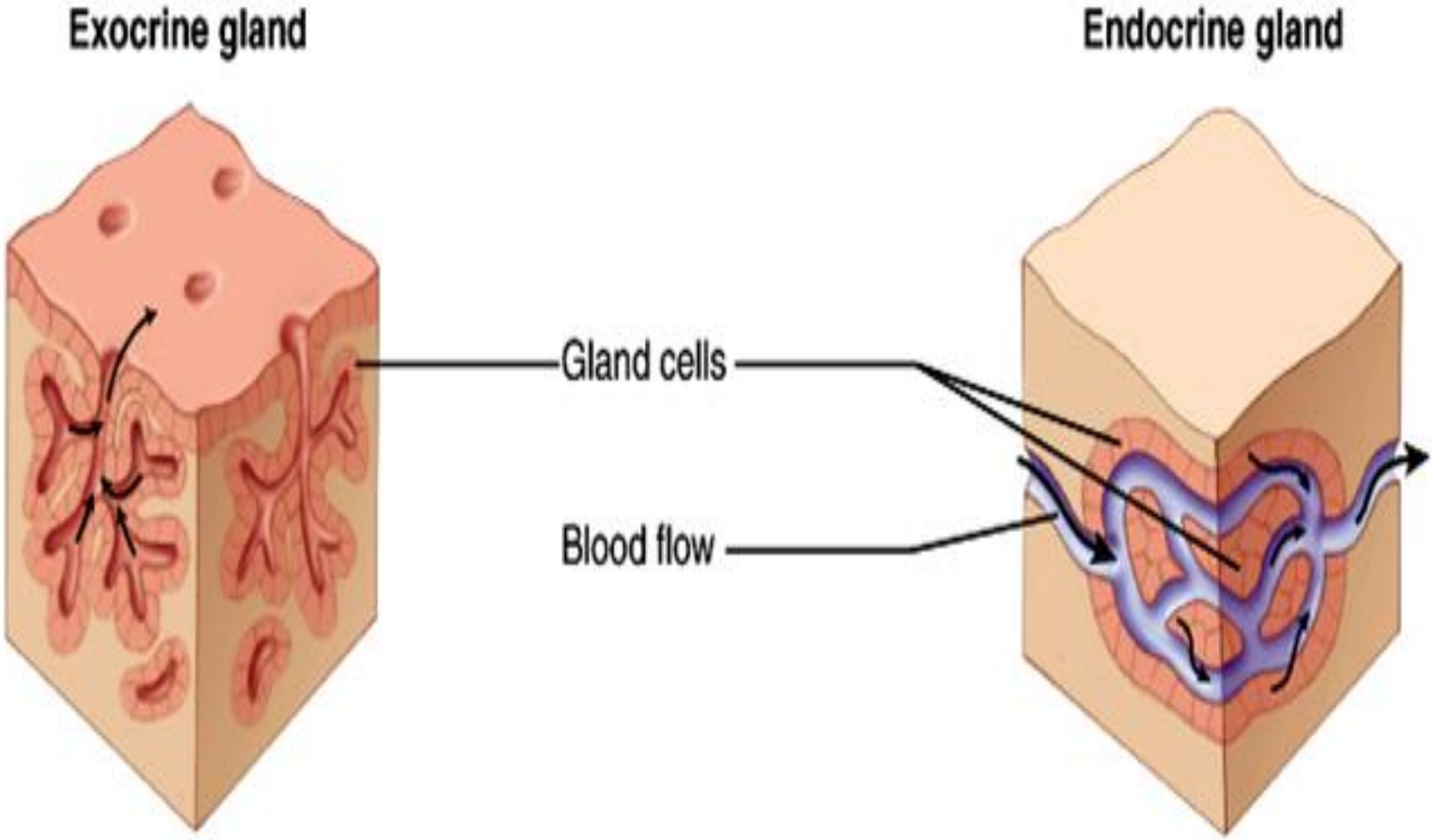

- **Classification of Exocrine glands**

1. structural classification

Types of gland	Description	Example
Simple tubular	Tubular secretory part is straight and attaches to a single unbranched duct	Glands in the large intestine
Simple Branched Tubular	Tubular secretory part is branched and attaches to a single unbranched duct	Gastric glands
Simple Coiled Tubular	Tubular secretory part is coiled and attaches to a single unbranched duct	Sweat glands
Simple Acinar	Secretory portion is rounded and attaches to a single unbranched duct	Glands of the penile urethra
Simple Branched Acinar	Secretory portion is branched and attaches to a single unbranched duct	Sebaceous glands
Compound Tubular	Secretory portion is tubular and attaches to a branched duct	Cowper's glands, and Brunner's gland of duodenum
Compound Acinar	Secretory portion is rounded and attaches to a branched duct	Mammary glands
Compound Tubuloacinar	Secretory portion is both tubular and rounded and attaches to a branched duct	Acinar glands of the pancreas, salivary gland

SIMPLE GLANDS

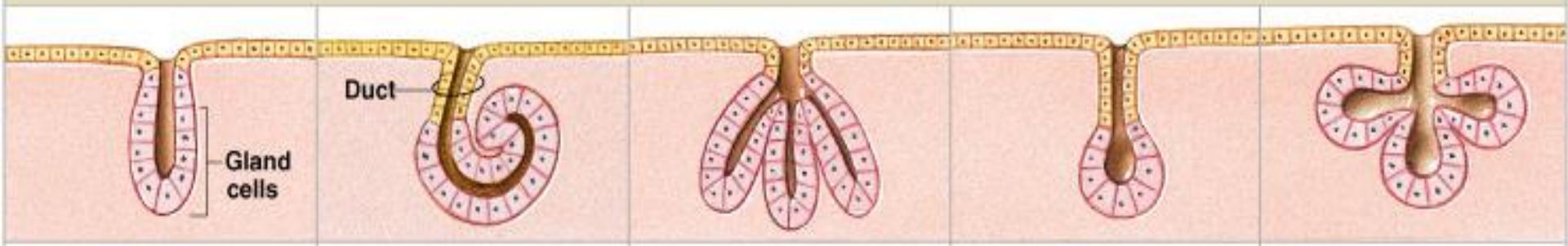

SIMPLE TUBULAR	SIMPLE COILED TUBULAR	SIMPLE BRANCHED TUBULAR	SIMPLE ALVEOLAR (ACINAR)	SIMPLE BRANCHED ALVEOLAR
Examples: Intestinal glands	*Examples:* Merocrine sweat glands	*Examples:* Gastric glands; Mucous glands of esophagus, tongue, duodenum	*Examples:* Not found in adult; a stage in development of simple branched glands	*Examples:* Sebaceous (oil) glands

COMPOUND GLANDS

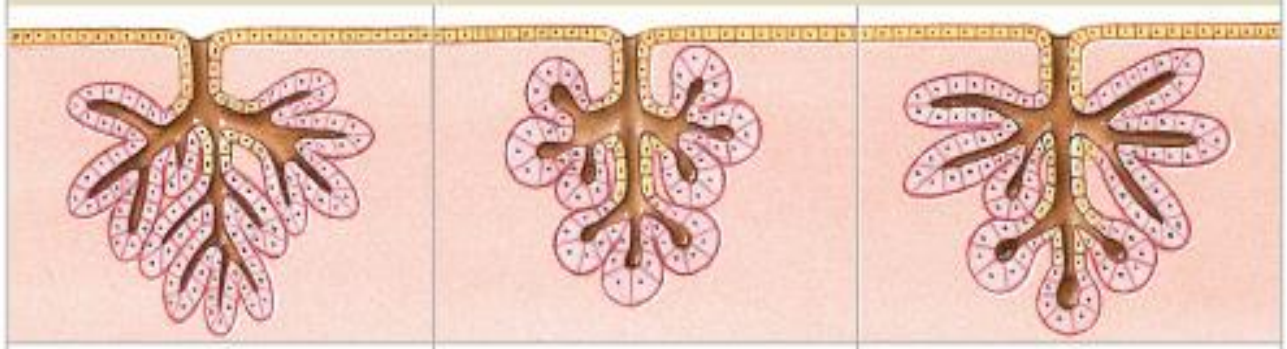

COMPOUND TUBULAR	COMPOUND ALVEOLAR (ACINAR)	COMPOUND TUBULOALVEOLAR
Examples: Mucous glands (in mouth); Bulbourethral glands (in male reproductive system); Testes (seminiferous tubules)	*Examples:* Mammary glands	*Examples:* Salivary glands; Glands of respiratory passages; Pancreas

tubular



acinar

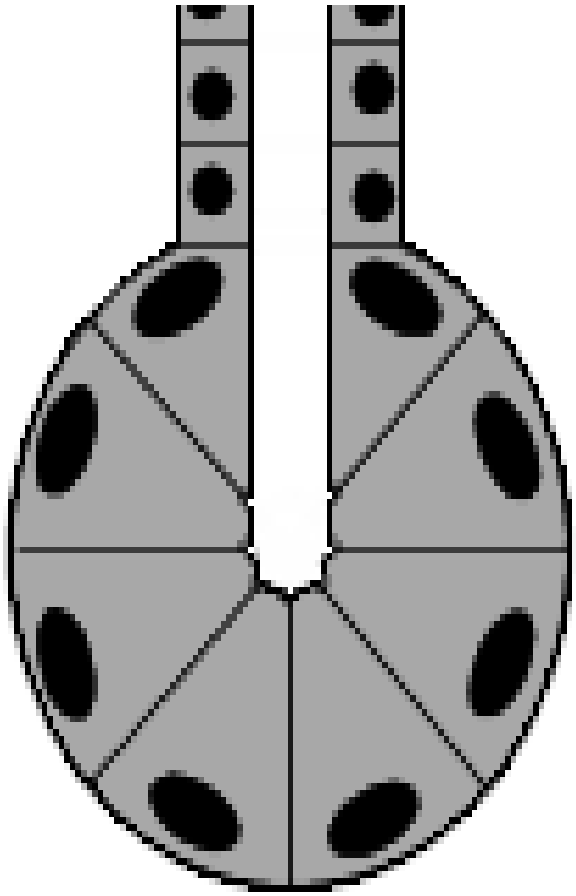

alveolar

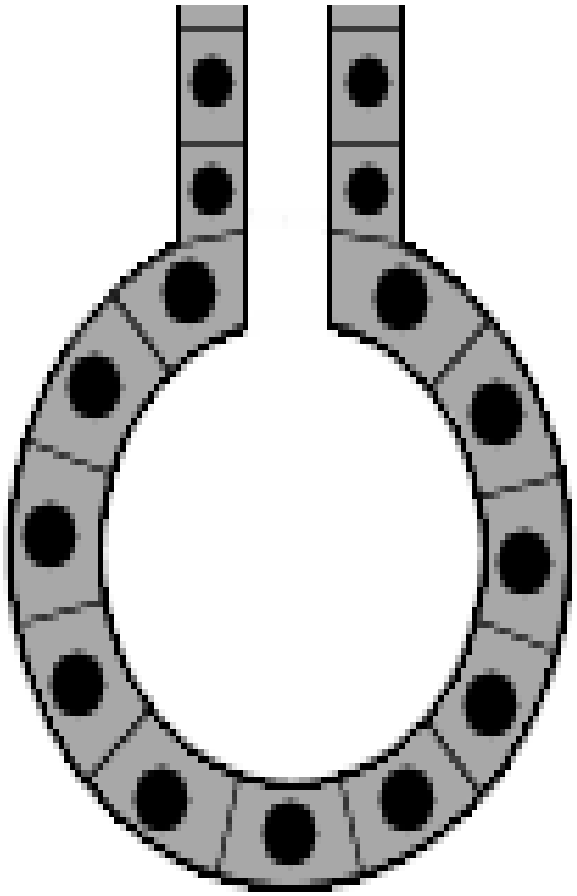

glands

2. Mode of secretion

Type of glands	Description	Secretion	Example
Merocrine	products distributed via exocytosis, cells remain intact	Continuous secretion Relatively Small secretion quantities	Sweat, salivary glands, goblet cells
Apocrine	products distributed by shedding the apical portion of the cell, the cell is damaged but not killed	Intermediate secretion moderate secretion quantities	Mammary glands, ceruminous glands
Holocrine	products distributed by cell lysis	Intermediate secretion large secretion quantities	Sebaceous (oil) glands

Holocrine

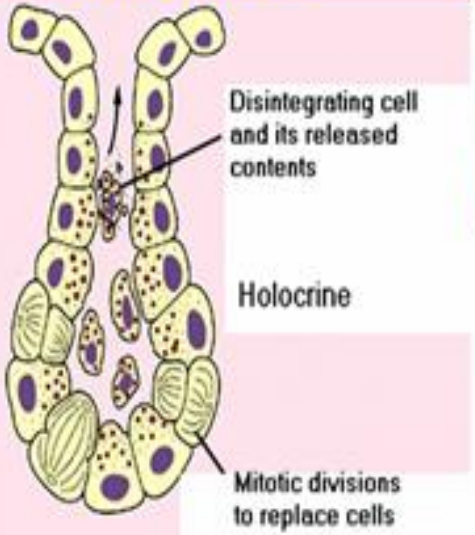

Apocrine

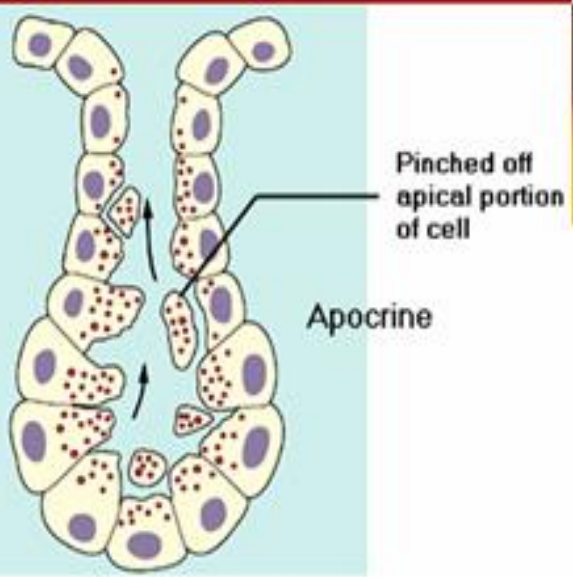

Merocrine

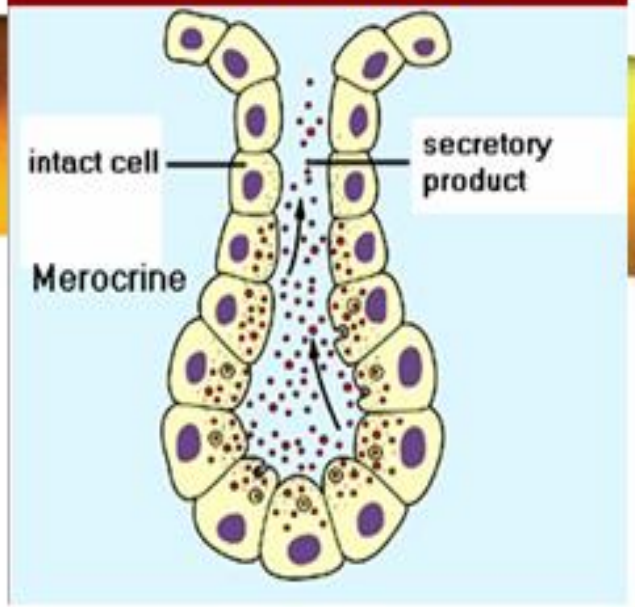

Sebaceous gland

Mammary Gland

Salivary gland

3. **Type of secretion**

Type of gland	Description	Example
serous	thin, watery fluid, product of serous cells, small pink staining cuboidal cells with spherical to elliptical nuclei	salivary glands, sweat glands, pancreatic acinar
mucous	thicker, viscous secretion, product of mucous cells, large blue staining cuboidal cells with flat, elongate nuclei	Stomach glands
mixed	Contain serous and mucous separately or mucous surrounded by part of serous	Submaxillar and sublingual glands
sebaceous	thick, lipid rich secretions of cuboidal cells in certain skin regions	face, nose, axillary

Capillary
Striated duct

Intercalated duct
Serous secretory units

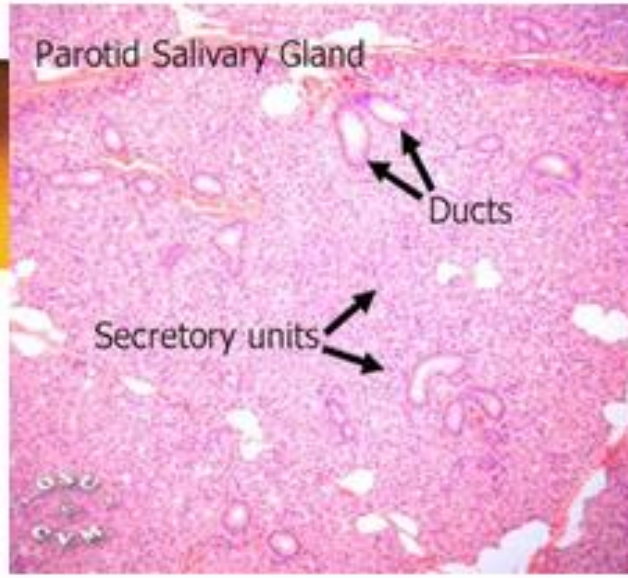
Parotid Salivary Gland
Ducts
Secretory units

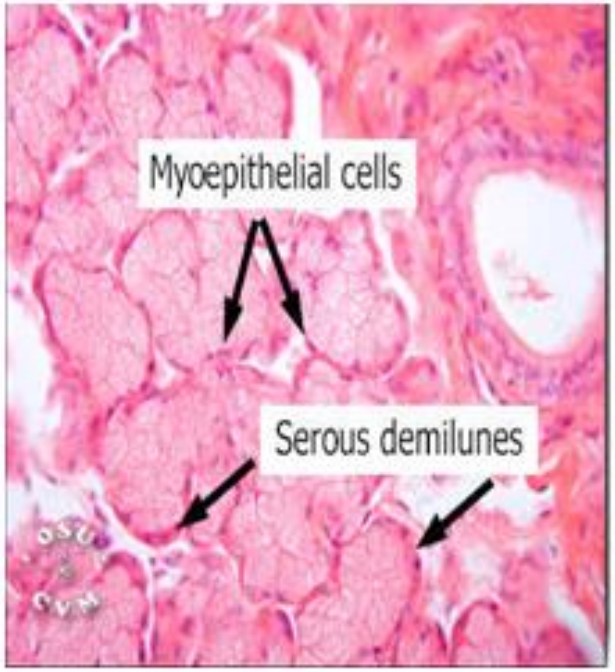
Myoepithelial cells
Serous demilunes

Duct
Secretory units

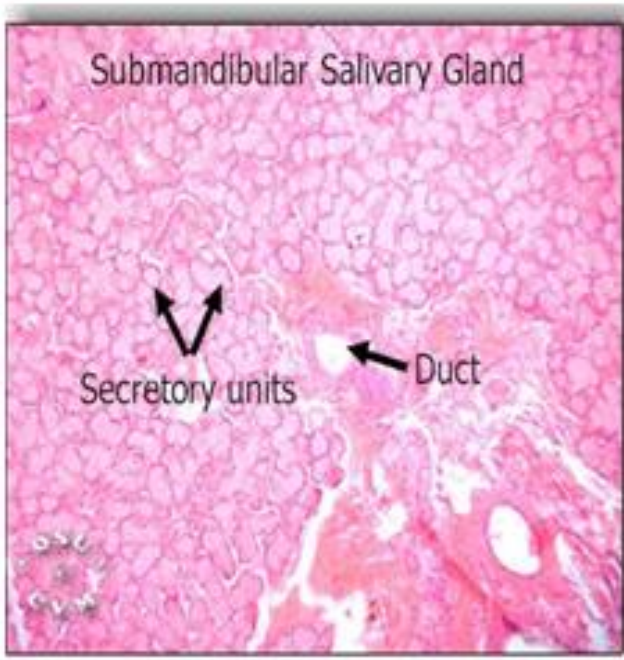
Submandibular Salivary Gland
Secretory units
Duct

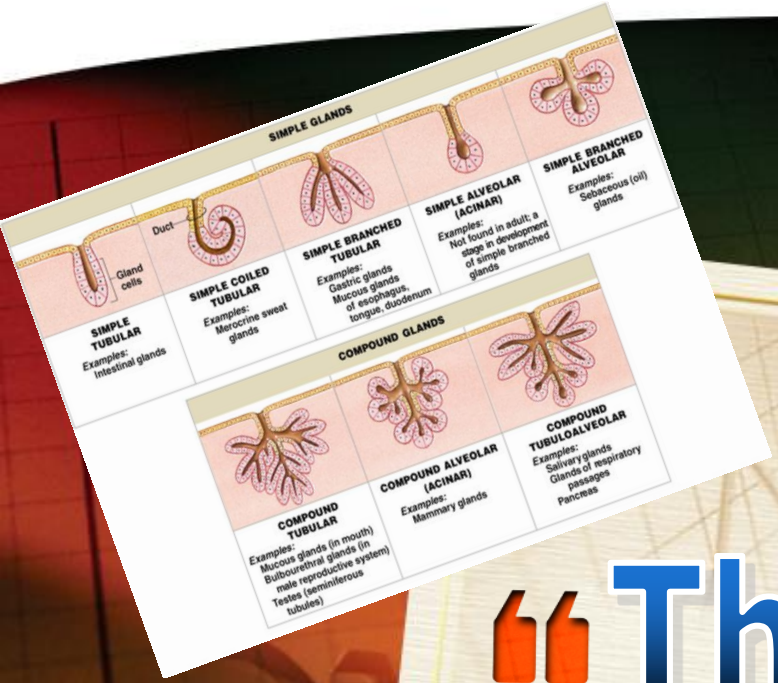
SIMPLE GLANDS
Gland cells
Duct
SIMPLE TUBULAR
Examples: Intestinal glands
SIMPLE COILED TUBULAR
Examples: Merocrine sweat glands
SIMPLE BRANCHED TUBULAR
Examples: Gastric glands Mucous glands of esophagus, tongue, duodenum
SIMPLE ALVEOLAR (ACINAR)
Examples: Not found in adult; a stage in development of simple branched glands
SIMPLE BRANCHED ALVEOLAR
Examples: Sebaceous (oil) glands
COMPOUND GLANDS
COMPOUND TUBULAR
Examples: Mucous glands (in mouth) Bulbourethral glands (in male reproductive system) Testes (seminiferous tubules)
COMPOUND ALVEOLAR (ACINAR)
Examples: Mammary glands
COMPOUND TUBULOALVEOLAR
Examples: Salivary glands Glands of respiratory passages Pancreas

“Thank You !”

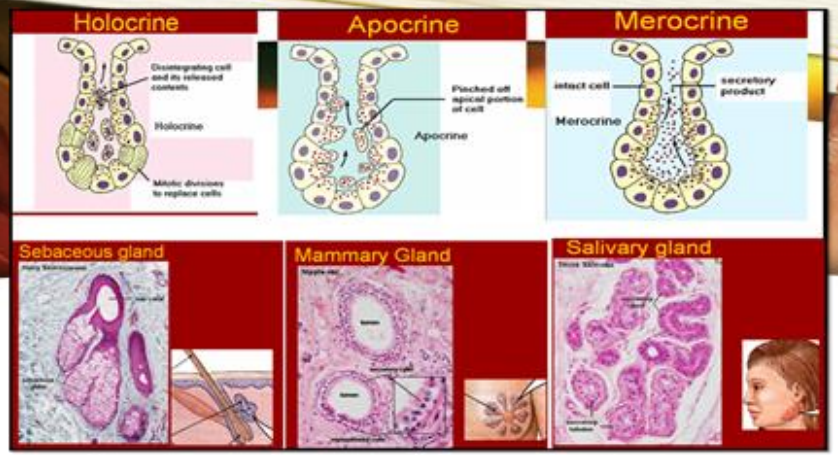
Holocrine
Disintegrating cell and its released contents
Holocrine
Mitotic divisions to replace cells
Apocrine
Pinched off apical portion of cell
Apocrine
Merocrine
intact cell
secretory product
Merocrine
Sebaceous gland
Mammary Gland
Salivary gland