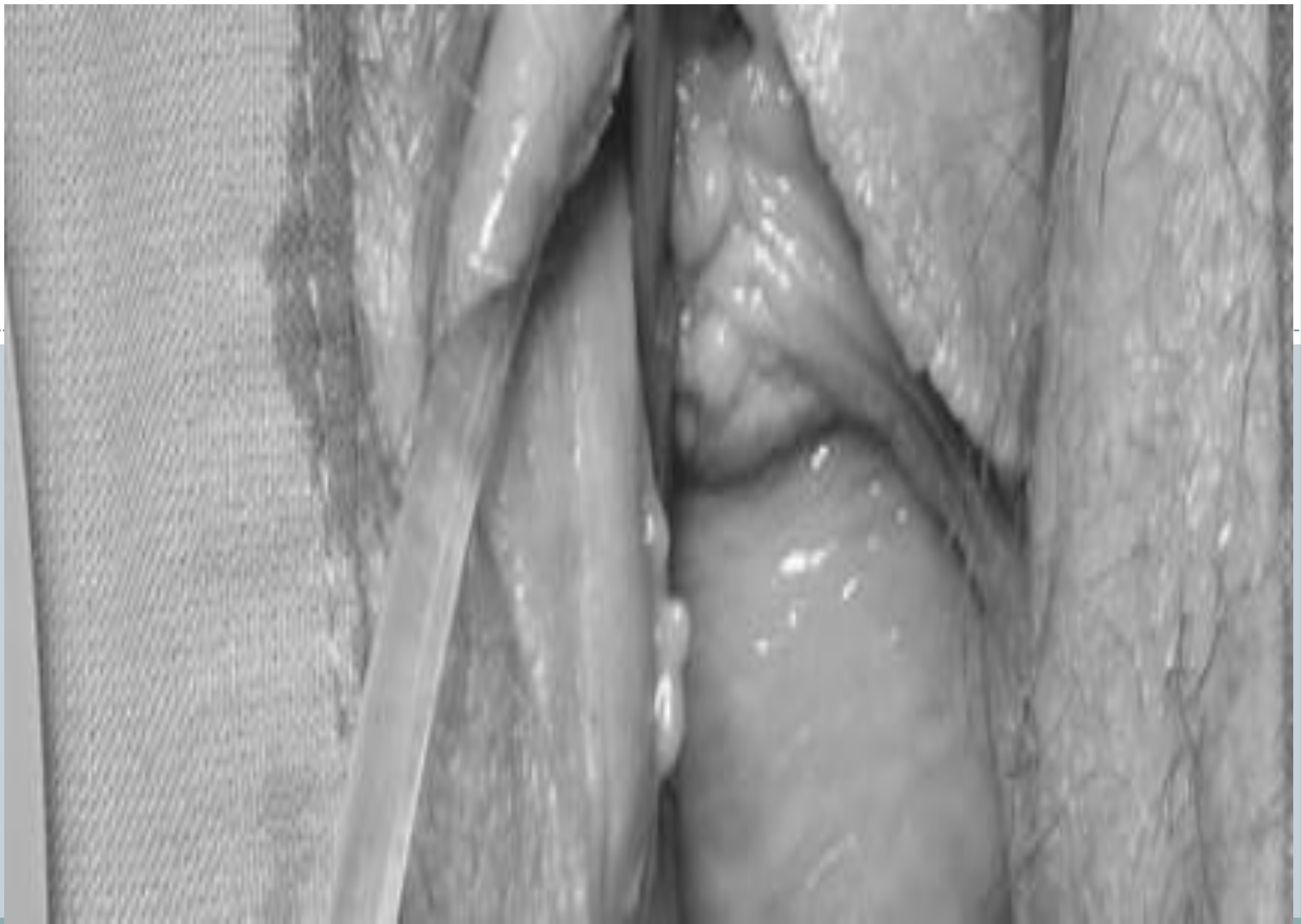
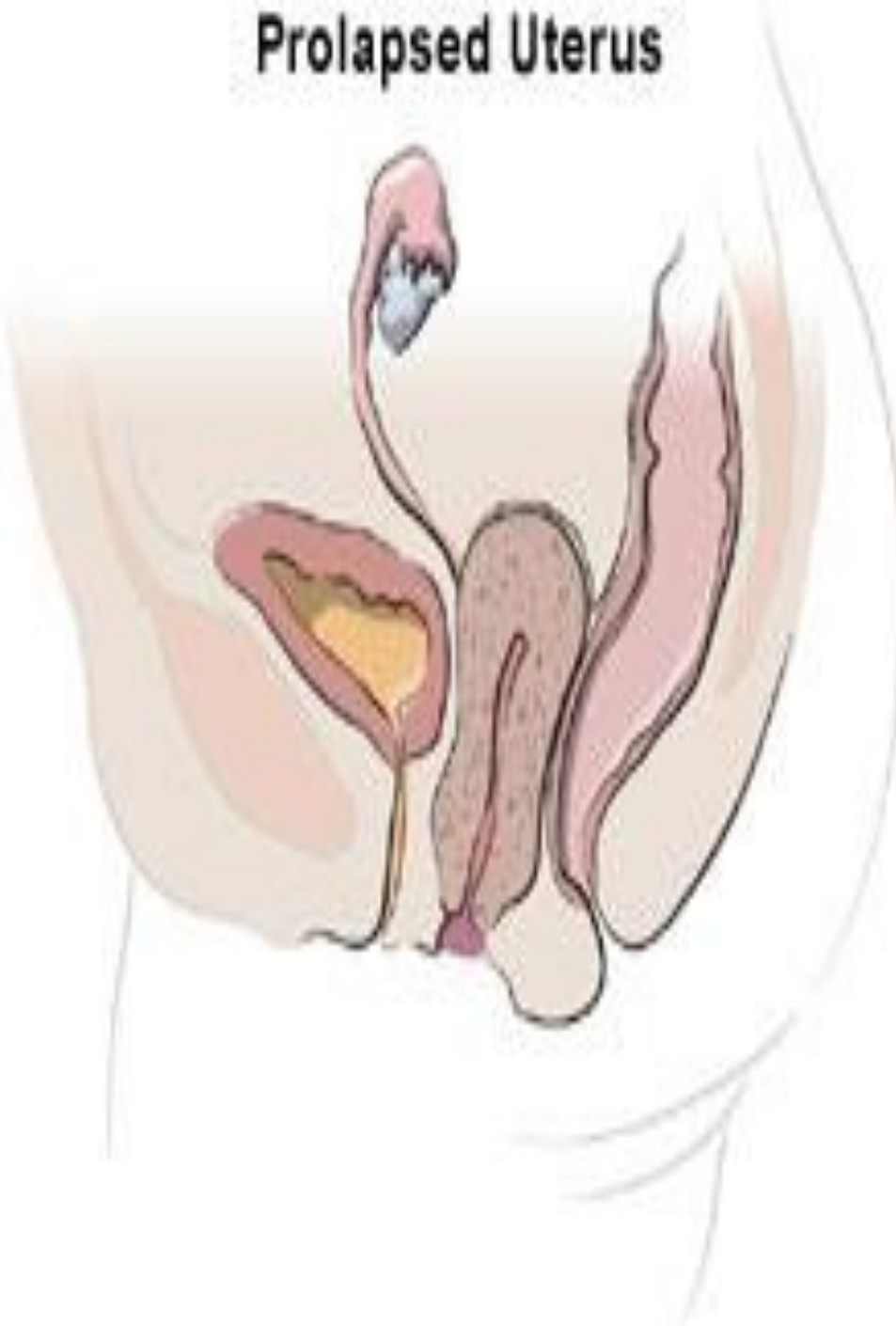
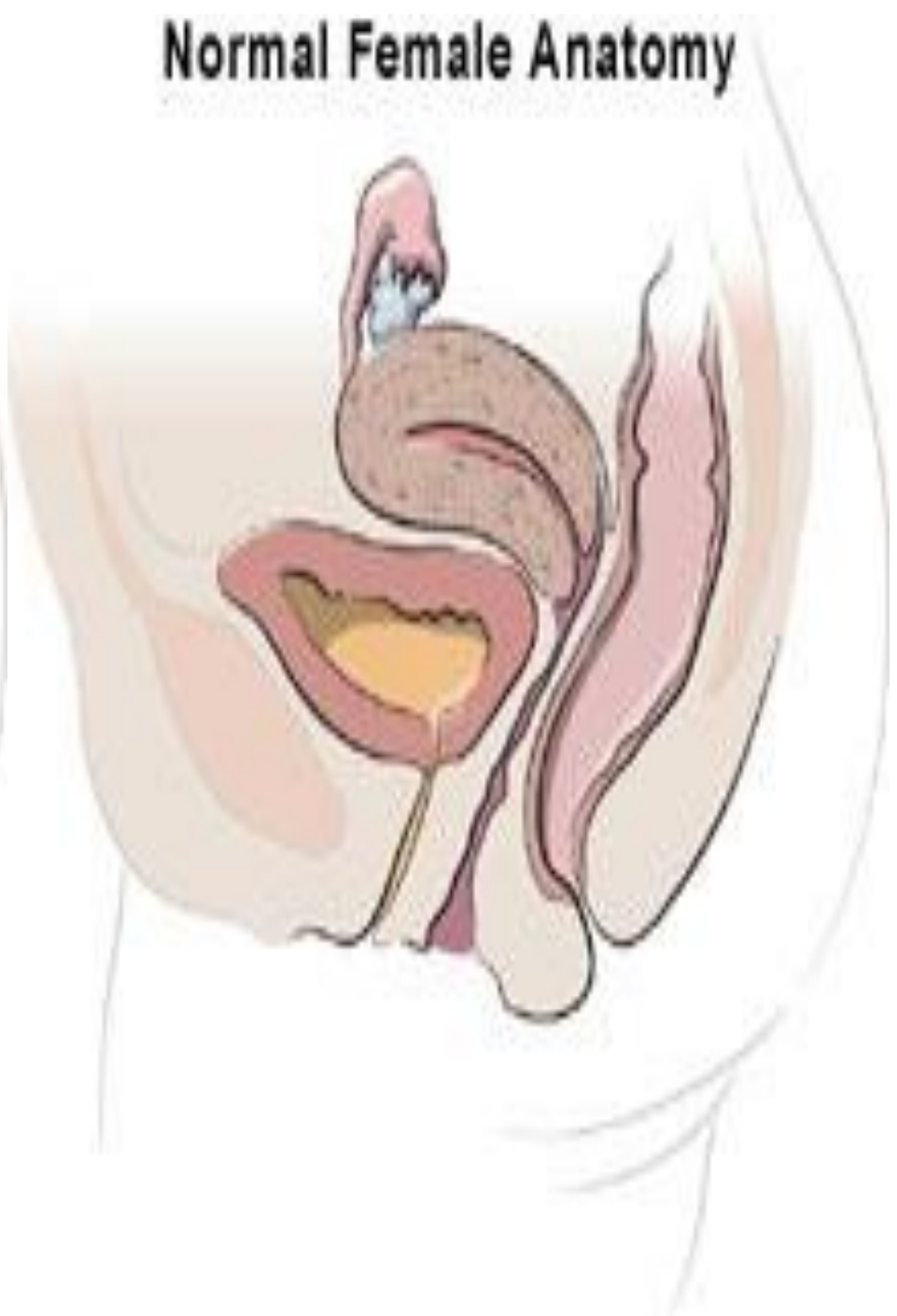

Prolapsed Uterus



Normal Female Anatomy

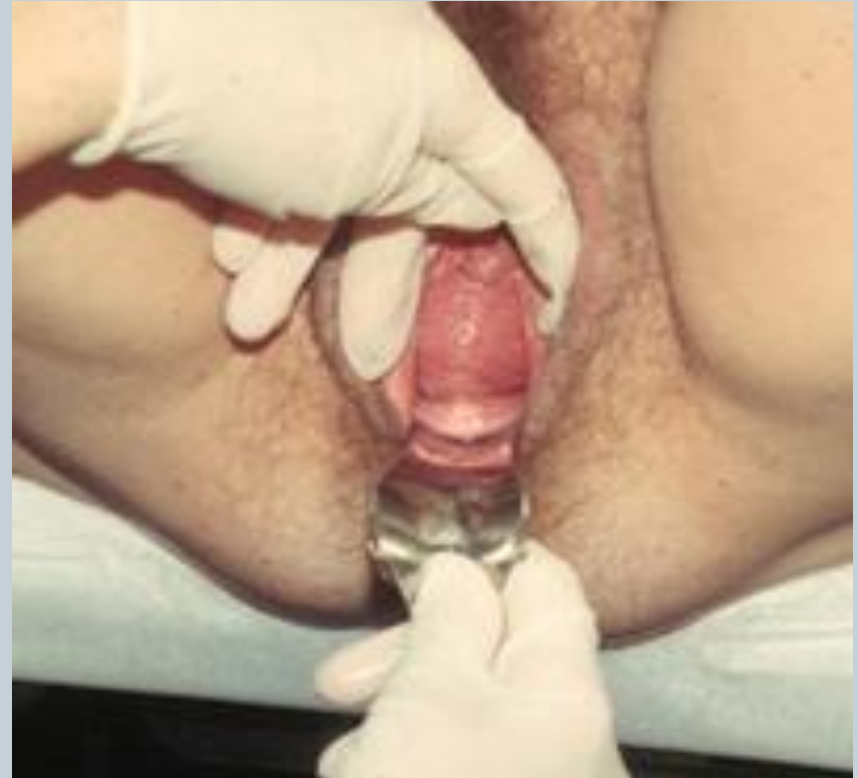
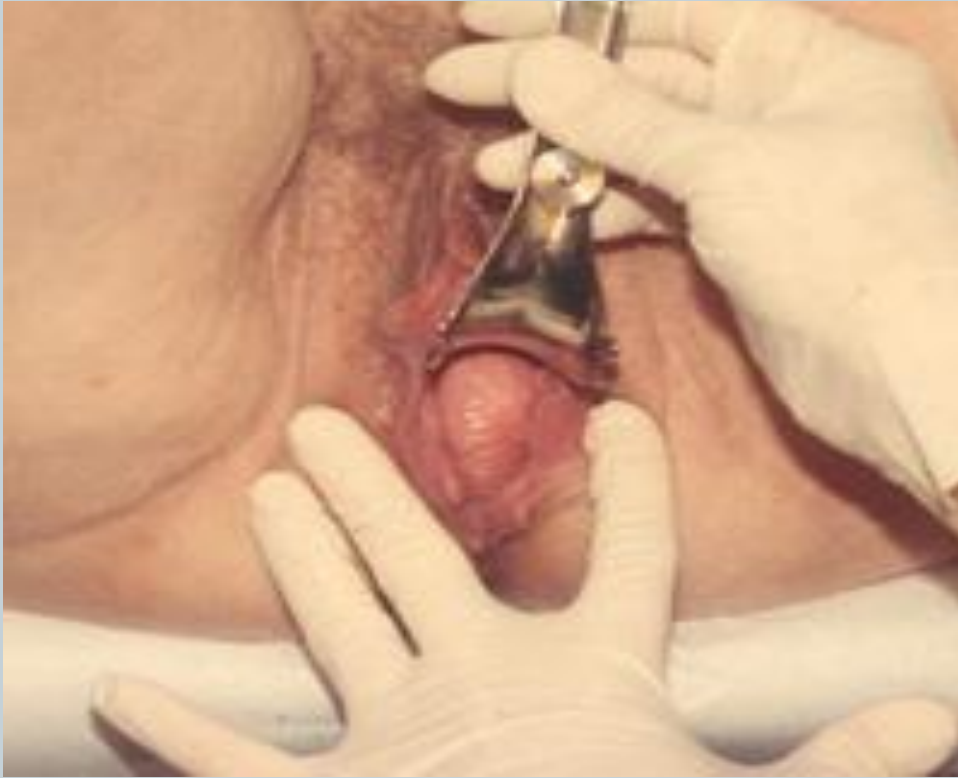
- **Genital Prolapse:**



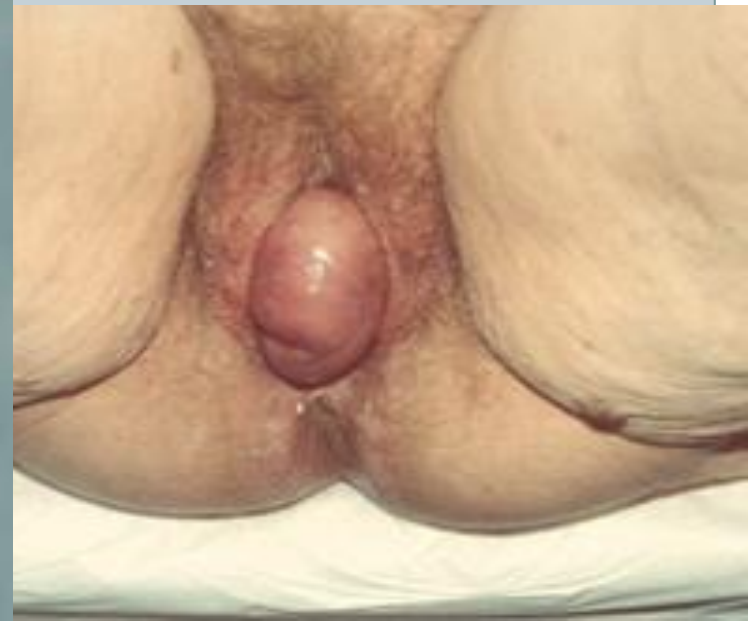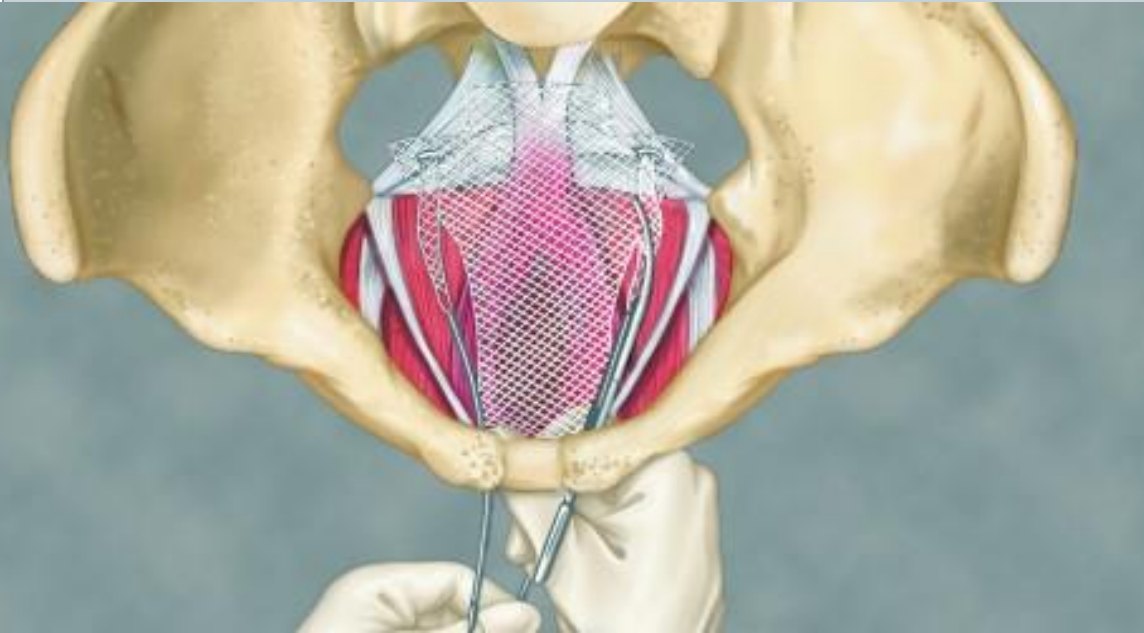- **Genitourinary prolapse occurs when there is descent of one or more of the pelvic organs including the uterus, bladder, rectum, small or large bowel, or vaginal vault.**
- **The anterior and/or posterior vaginal walls, the uterus and the vaginal vault can all be affected by this descent.**

There is resulting protrusion of the vaginal walls and/or the uterus. It is usually accompanied by urinary, bowel, sexual, or local pelvic symptoms.



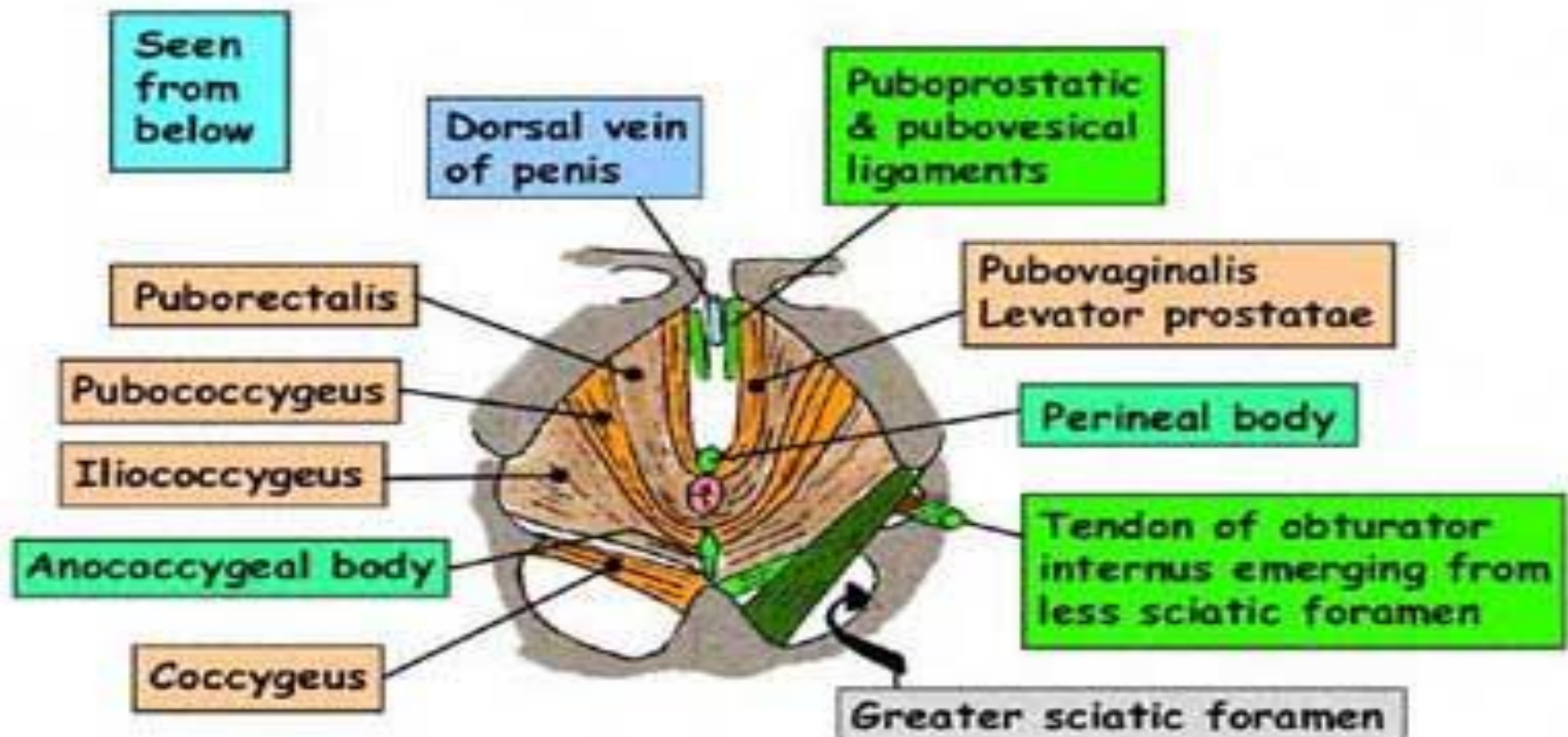
Patho-physiology:

- The pelvic organs are mainly supported by the levator ani muscles and the endopelvic fascia (a connective tissue network connecting the organs to the pelvic muscles and bones).



PELVIC FLOOR

- Covered superiorly and inferiorly with fascia (epimysium)
- Nerve supply for levator ani is perineal branch of S4. S5 for coccygeus



- **Genitourinary prolapse occurs when this support structure is weakened through direct muscle trauma, neuropathic injury, disruption or stretching.**
- **A multifactorial cause for this damage is likely.**
- **The orientation and shape of the bones of the pelvis have also been implicated in the pathogenesis of genitourinary prolapse.**

Confirmed risk factors:

- Increasing age (risk doubles with each decade of life).
- Vaginal delivery.
- Increasing parity.
- Overweight (BMI 25-30) and obesity (BMI >30).
- Spina bifida and spina bifida occulta.
- Possible risk factors:
 - Intrapartum variables (controversial and unproven):
 - Fetal macrosomia.

- - **Prolonged second stage of labour.**

- **Episiotomy.**

- **Anal sphincter injury.**

- **Epidural anaesthesia.**

- **Use of forceps.**

- **Use of oxytocin.**

- **Age <25 years at first delivery.**

- **Race.**

- **Family history of prolapse.**

- **Constipation.**

- **Connective tissue disorders, eg Marfan's syndrome, Ehlers-Danlos syndrome.**

- **Previous hysterectomy.**

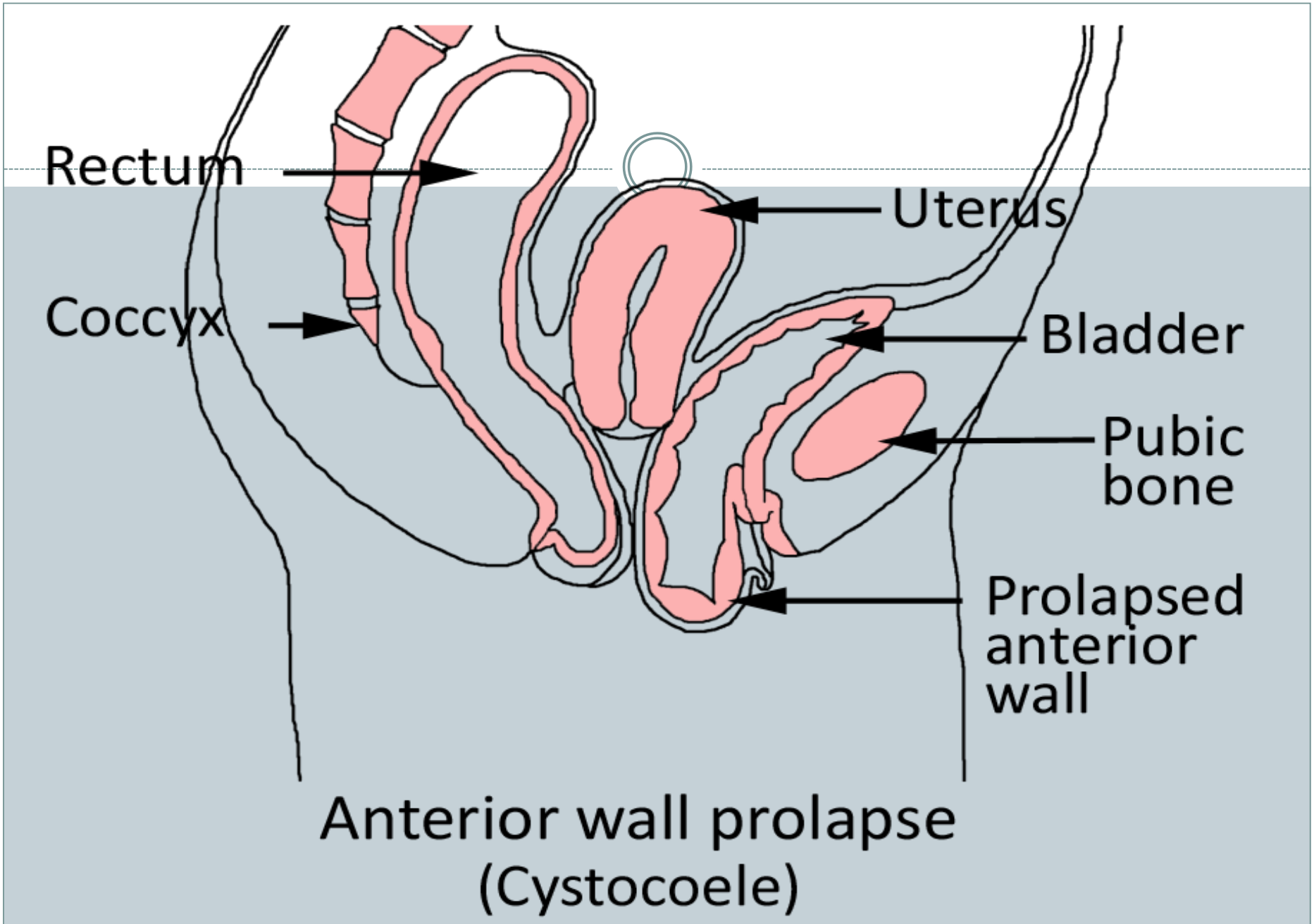
• **Types of genitourinary prolapse**

- Prolapse can occur in the anterior, middle, or posterior compartment of the pelvis:
- **Anterior compartment prolapse**
- **Urethrocele:** prolapse of the urethra into the vagina. Frequently associated with urinary stress incontinence.

- **Cystocele:**

prolapse of the bladder into the vagina. A large cystocele may cause increased urinary frequency, frequent urinary infections and produce a pressure sensation or mass at the introitus.

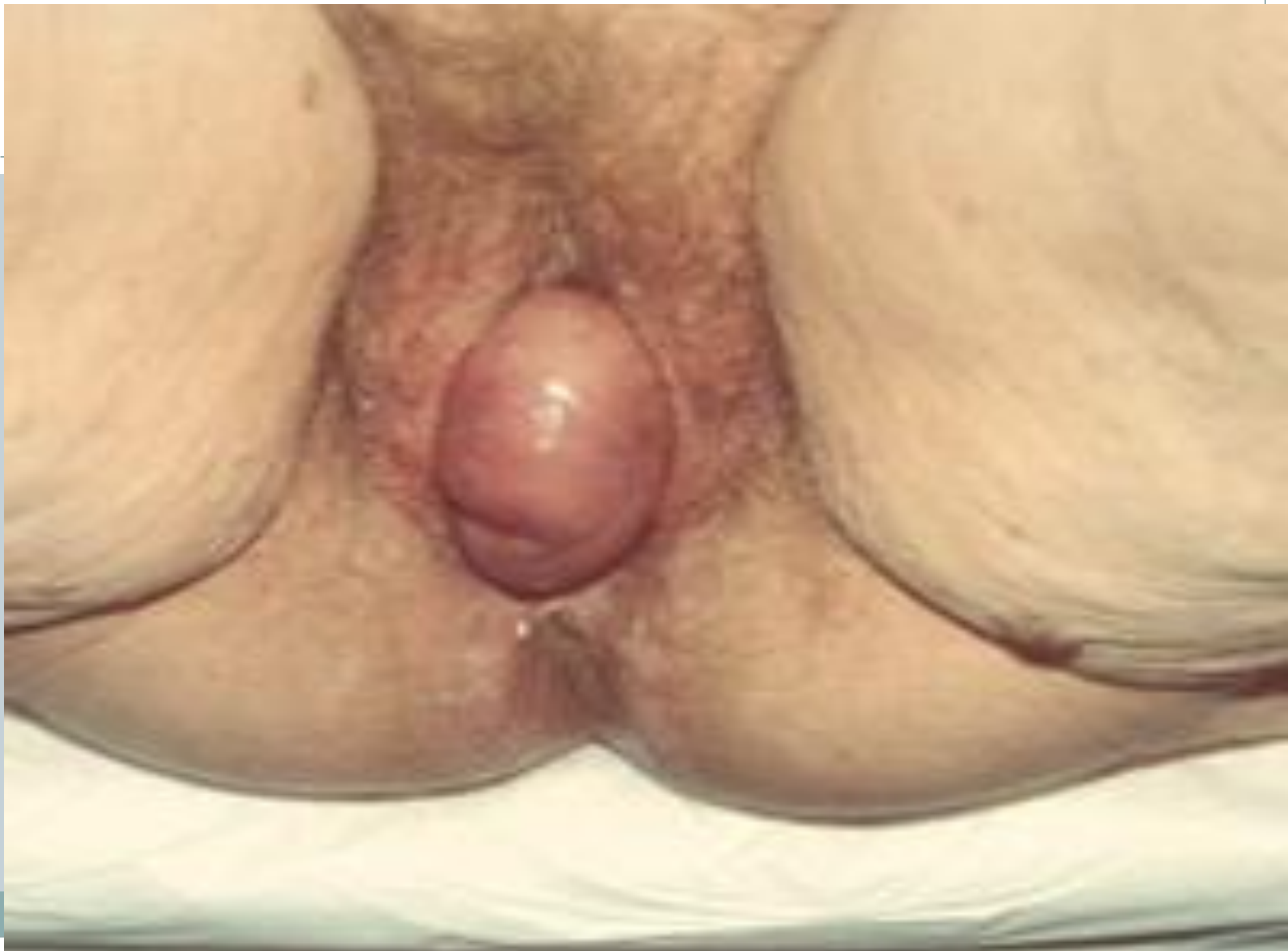- **Cystourethrocele:** prolapse of both urethra and bladder.



- **Middle compartment prolapse**

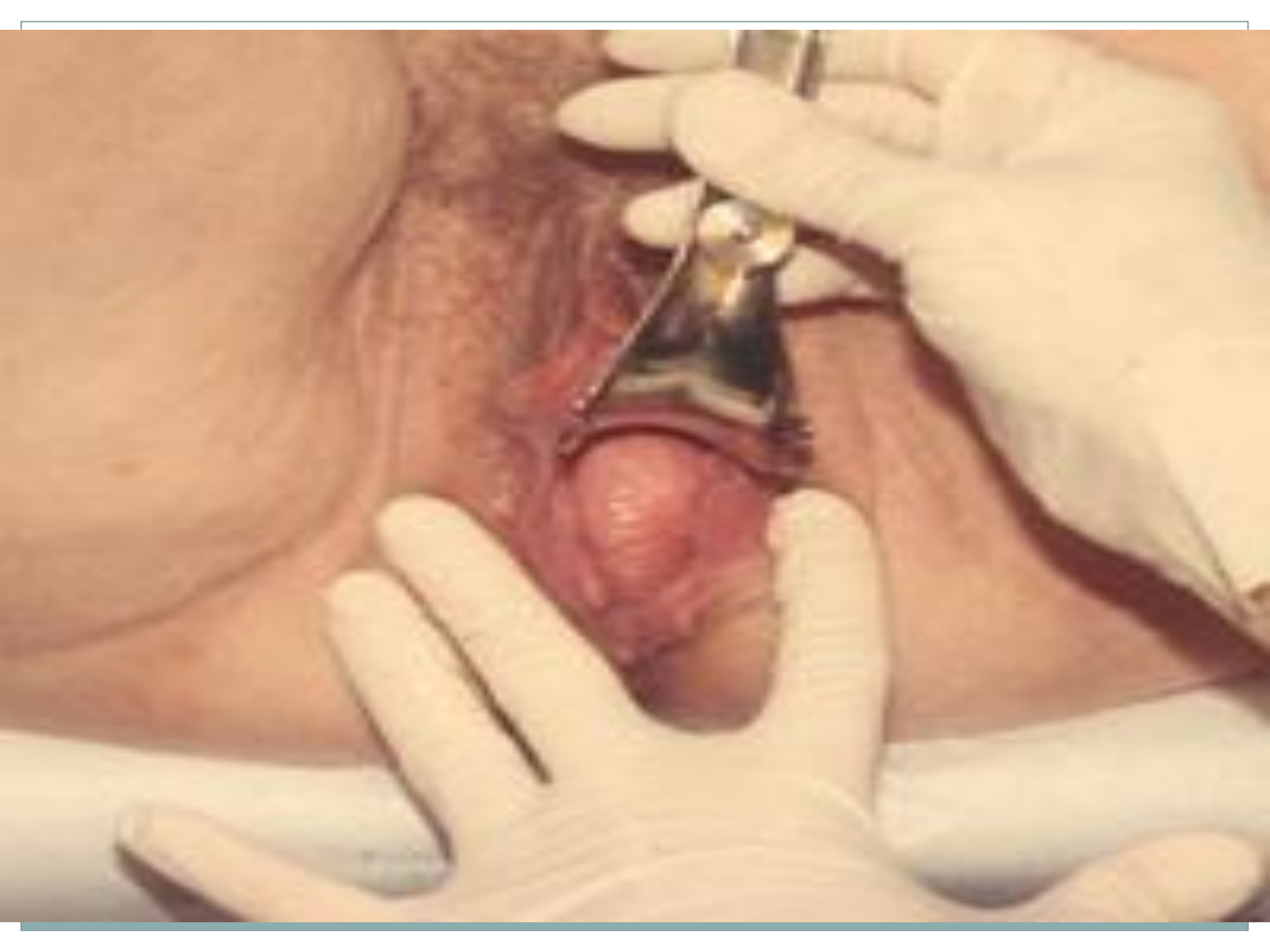- **Uterine prolapse:** descent of the uterus into the vagina.

- **Vaginal vault prolapse:** descent of the vaginal vault post-hysterectomy. Often associated with cystocele, rectocele, and enterocele. With complete inversion, the urethra, bladder, and distal ureters may be included resulting in varying degrees of retention and distal ureteric obstruction.



- **Enterocele:** herniation of the pouch of Douglas (including small intestine/omentum) into the vagina.
- Can occur following pelvic surgery. Can be difficult to differentiate clinically from rectocele but a cough impulse can be felt in enterocele on combined rectal and vaginal examination.

- **Posterior compartment prolapse**
- **Rectocele:** prolapse of the rectum into the vagina.
- Cysto-urethrocele is the most common type of prolapse, followed by uterine prolapse and then rectocele. Urethroceles are rare.



The degree of uterine descent can be graded as:

- **1st degree:**

cervix visible when the perineum is depressed -it is contained within the vagina.

- **2nd degree:**

cervix prolapsed through the introits with the fundus remaining in the pelvis.

- **3rd degree:**

procidentia (complete prolapse) - entire uterus is outside the introits.

Note the descent of the cervix which is accompanied by stretching of the ligaments and by supravaginal elongation of the cervix.

Classification of Prolapse

Anterior Vaginal Wall:

Upper Two-Thirds-Cystocele.

Lower One-Third-Urethrocele

} Cystourethrocele

Posterior Vaginal Wall:

Upper One-Third-Enterocoele (Pouch of Douglas Hernia)

Lower Two-Thirds-Rectocele

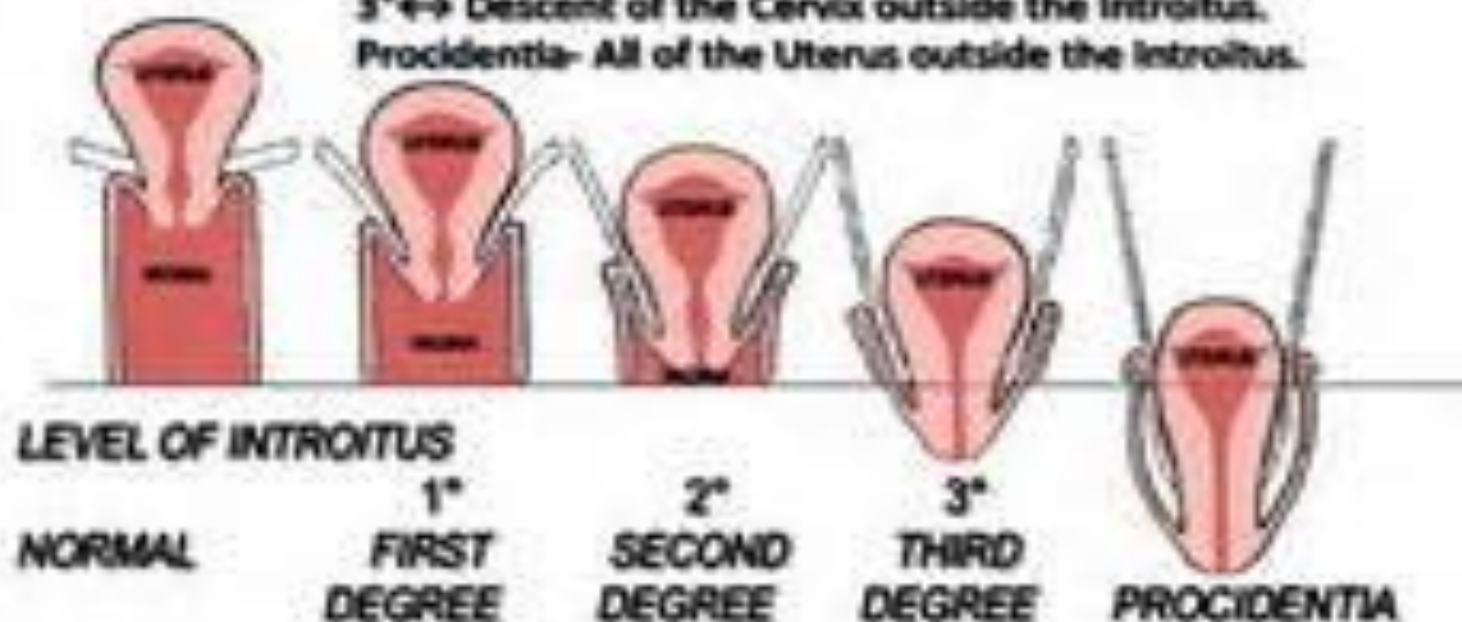
UTERINE DESCENT:

1° ↔ Descent of the Cervix in the Vagina.

2° ↔ Descent of the Cervix to the Introitus.

3° ↔ Descent of the Cervix outside the Introitus.

Procidentia- All of the Uterus outside the Introitus.



Symptoms:

- **Mild prolapse may be asymptomatic and an incidental finding.**
- **Sometimes symptoms can severely affect their quality of life.**
- **Symptoms are related to the site and type of prolapse.**
- **Vaginal/general symptoms can be common to all types of prolapse.**

Vaginal/general symptoms

- **Sensation of pressure, fullness or heaviness.**
- **Sensation of a bulge/protrusion or 'something coming down'.**
- **Seeing or feeling a bulge/protrusion.**
- **Difficulty retaining tampons.**
- **Spotting (in the presence of ulceration of the prolapse).**

- **Urinary symptoms**
- **Incontinence.**
- **Frequency.**
- **Urgency.**
- **Feeling of incomplete bladder emptying.**
- **Weak or prolonged urinary stream.**
- **The need to reduce the prolapse manually before voiding.**
- **The need to change position to start or complete voiding.**



Coital difficulty

- Dyspareunia.
- **Loss of vaginal sensation.**
- **Vaginal flatus.**

Bowel symptoms

- Constipation/straining.
- Urgency of stool.
- Incontinence of flatus or stool.
- Incomplete evacuation.
- The need to apply digital pressure to the perineum or posterior vaginal wall to enable defecation (splinting).
- Digital evacuation necessary to pass a stool.

Examination:



- Examine the patient in both a standing and left lateral position if possible.
- Use a Sims' speculum inserted along the posterior vaginal wall to assess the anterior wall and vaginal vault and vice versa. Ask the patient to strain.
- Uterine descent can be assessed by gentle traction with a vulsellum.

A bivalve speculum:

can also be used to identify the cervix or vaginal vault.

Ask the patient to strain, and slowly remove the speculum.

Look for the degree of descent of the vaginal apex.

- **Determine the parts of the vagina (anterior, posterior or apical) that the prolapse affects.**

Ulceration and hypertrophy of the cervix or vaginal mucosa with concomitant bleeding may be seen in women with prolapse that protrudes beyond the hymen.

- A rectal examination can be helpful if there are bowel symptoms**

- **Investigations:**



Diagnosis is usually clinical and based on history and examination.

- **If there are urinary symptoms consider the following:**

- **Urinalysis ± a mid-stream specimen of urine (MSU).**
- **Post-void residual urine volume testing using a catheter or bladder ultrasound scan.**

○ Urodynamic investigations:

○ Cystometry.

○ Urea and creatinine.

○ Renal ultrasound scan.

● **If there are bowel symptoms consider :**

○ Anal manometry.

- **Management:**

- **No treatment is necessary if incidental asymptomatic mild prolapse is found.**

There is no evidence about how to treat these women.

- **The management options for women with symptomatic genitourinary prolapse are:**

- Watchful waiting
- Vaginal pessary insertion
- Surgery

- **Conservative treatment options:**

- **Lifestyle modification:**

including treatment of cough, smoking cessation, constipation and overweight and obesity.

- **Pelvic floor muscle exercises:**

There is no definite evidence for the benefit of pelvic floor muscle exercises in the management of uterine prolapse

○ **. It may be beneficial as primary therapy for early stages of uterine prolapse.**

○ **Vaginal oestrogen creams:**

some advocate a trial of topical oestrogen cream for 4-6 weeks if prolapse is mild but there is no current evidence of any benefit.

- **Vaginal pessary insertion:**



A good alternative to surgery.

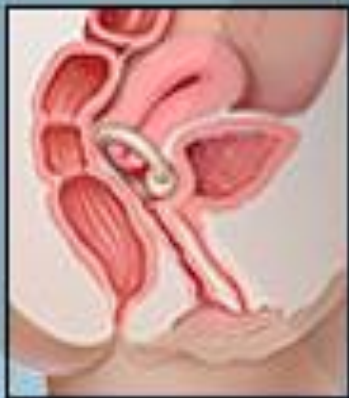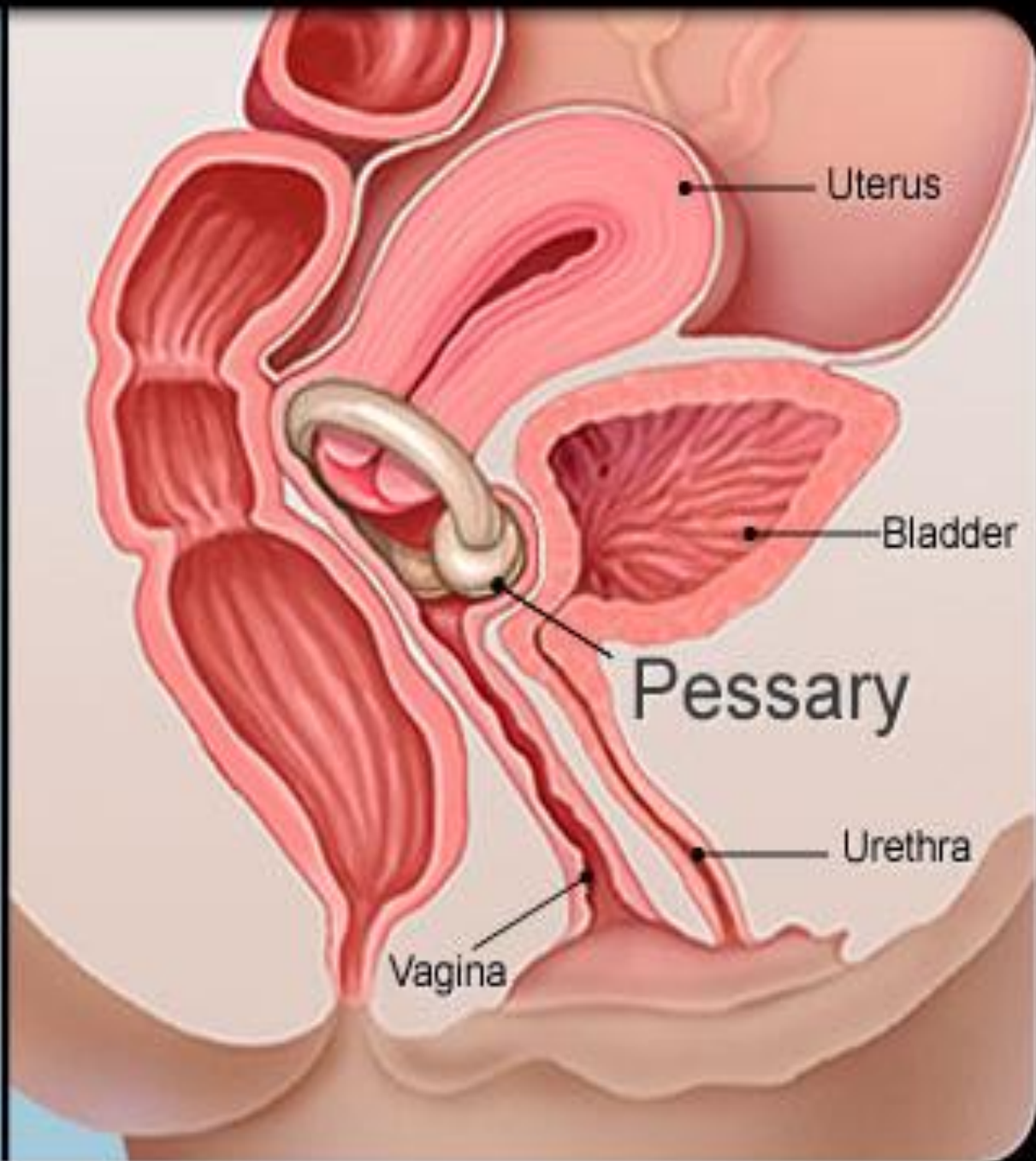
- **Inserted into the vagina to reduce the prolapse, provide support and relieve pressure on the bladder and bowel.**
- **Made of silicone or plastic.**

Pessaries are effective:

- **- As a test if symptoms due to prolapse.**
- **- If pregnancy planned.**
- **For short-term relief of prolapse prior to surgery.**
- **In the long term if surgery is not wanted or is contra-indicated.**

● **Fitting a pessary:** ○

- Ensure the patient's bladder and bowel are empty
- Perform a bimanual examination and estimate the size of the vagina.
- The aim is to fit the largest pessary that does not cause discomfort.
- Ask the patient after insertion to walk around, bend and micturate to ensure that the pessary is retained.




- **Surgery**
- **Surgery is very effective.**
- **Indications for surgery are:**
 - **failure of pessary.**
 - **patient who wants definitive treatment.**
 - **prolapse combined with urinary or faecal incontinence.**

- **Urinary incontinence may be masked by prolapse and can be precipitated by surgery.**
- **Some operations, eg colposuspension for a cystourethrocele, may predispose to a prolapse in another compartment.**

• The choice of procedure will depend on:

- whether the woman is sexually active.**
- Not complete family.**
- the fitness of the patient.**
- and surgeon's preference.**

- **Types of Surgery:** 
- **Vaginal Operation:**
- **Ant., Post. Repair, Vag. Hysterectomy.**
- **TVT, TOT.**
- **Abdominal :**
- **Laparoscopic.**
- **Colpo-suspension, sling operations.**
- **Oblitrative:**

- **Advice Post operative:**
- **If the prolapse remains corrected and the patient conceives, an elective Caesarean section may be advisable.**
- **Generally women should avoid heavy lifting after surgery and avoid sexual intercourse for 6-8 weeks.**

- **Surgery for bladder/urethral prolapse**

- **Anterior colporrhaphy:**

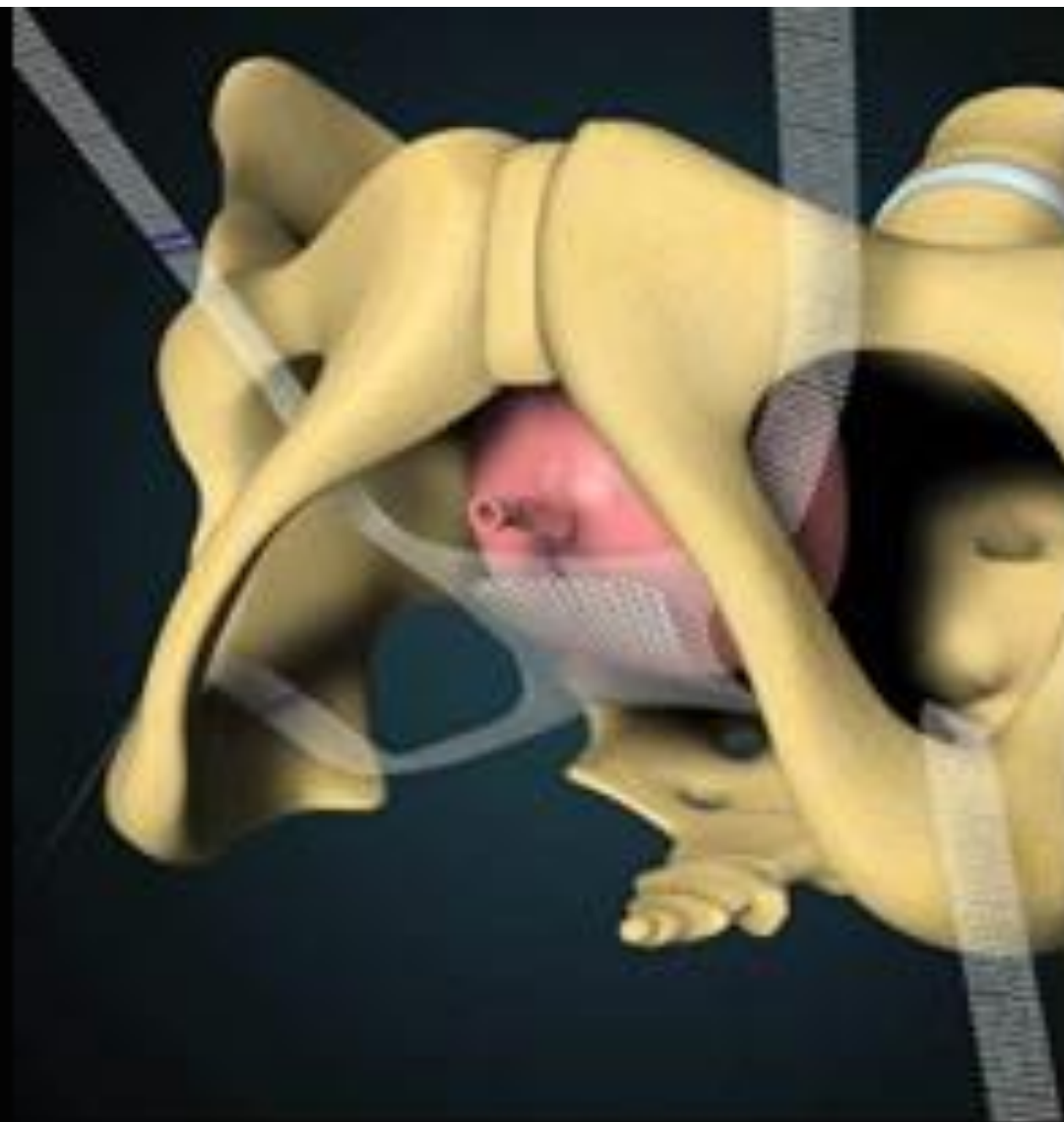
involves central plication of the fibro-muscular layer of the anterior vaginal wall. Mesh reinforcement may be used. Performed trans-vaginally.

- **Intra-operative complications are uncommon but haemorrhage, haematoma, and cystotomy may occur.**

Colposuspension:

performed for urethral sphincter incontinence associated with a cystourethrocele.

The paravaginal fascia on either side of the bladder neck and the base of the bladder are approximated to the pelvic side wall by sutures placed through the ipsilateral iliopectineal ligament.



Prolapse surgery to correct a dropped bladder is known as a sling surgery to lift and hold the bladder back in the correct position.

- **Surgery for uterine prolapse**

- **Hysterectomy:**

a vaginal hysterectomy has the advantage that no abdominal incision is needed, thereby reducing pain and hospital stay. This can be combined with anterior or posterior colporrhaphy.

- **Abdominal or laparoscopic sacrohysteropexy:**

performed if the woman wishes to retain her uterus. The uterus is attached to the anterior longitudinal ligament over the sacrum. Mesh is used to hold the uterus in place.

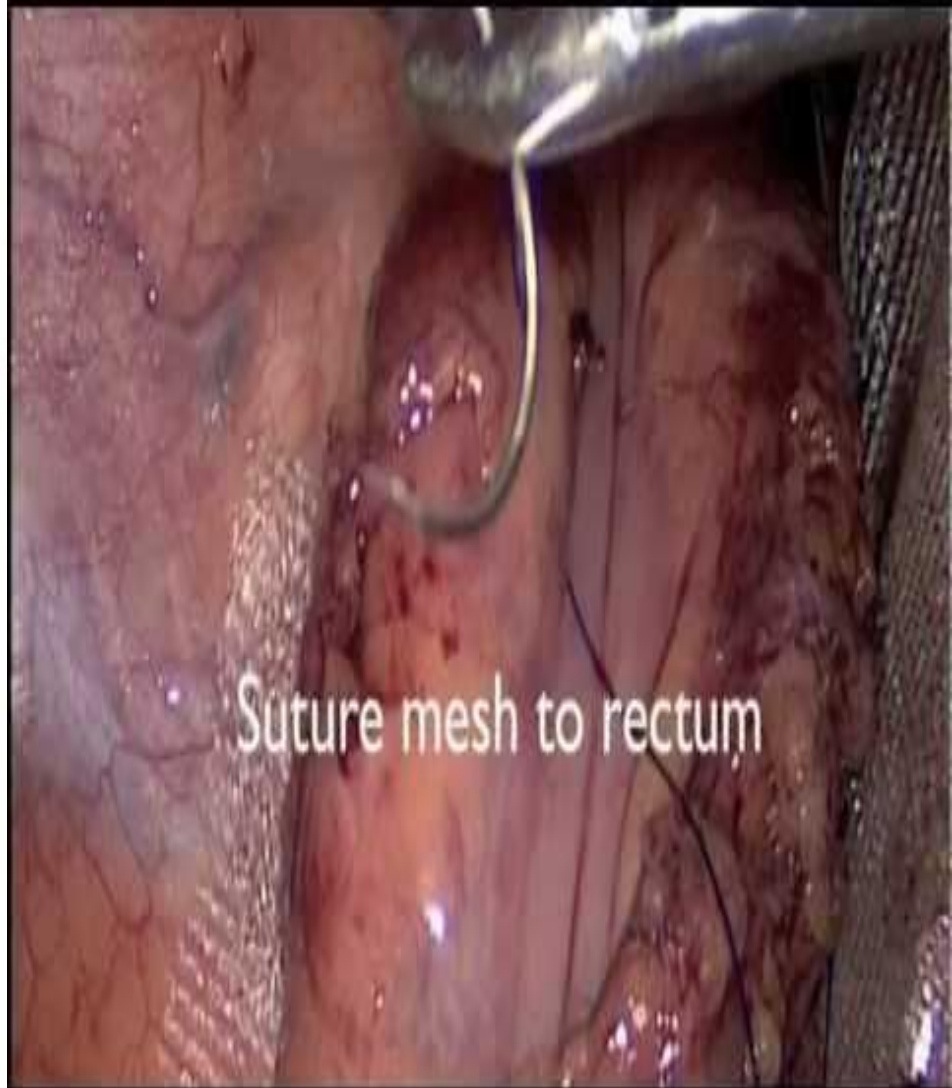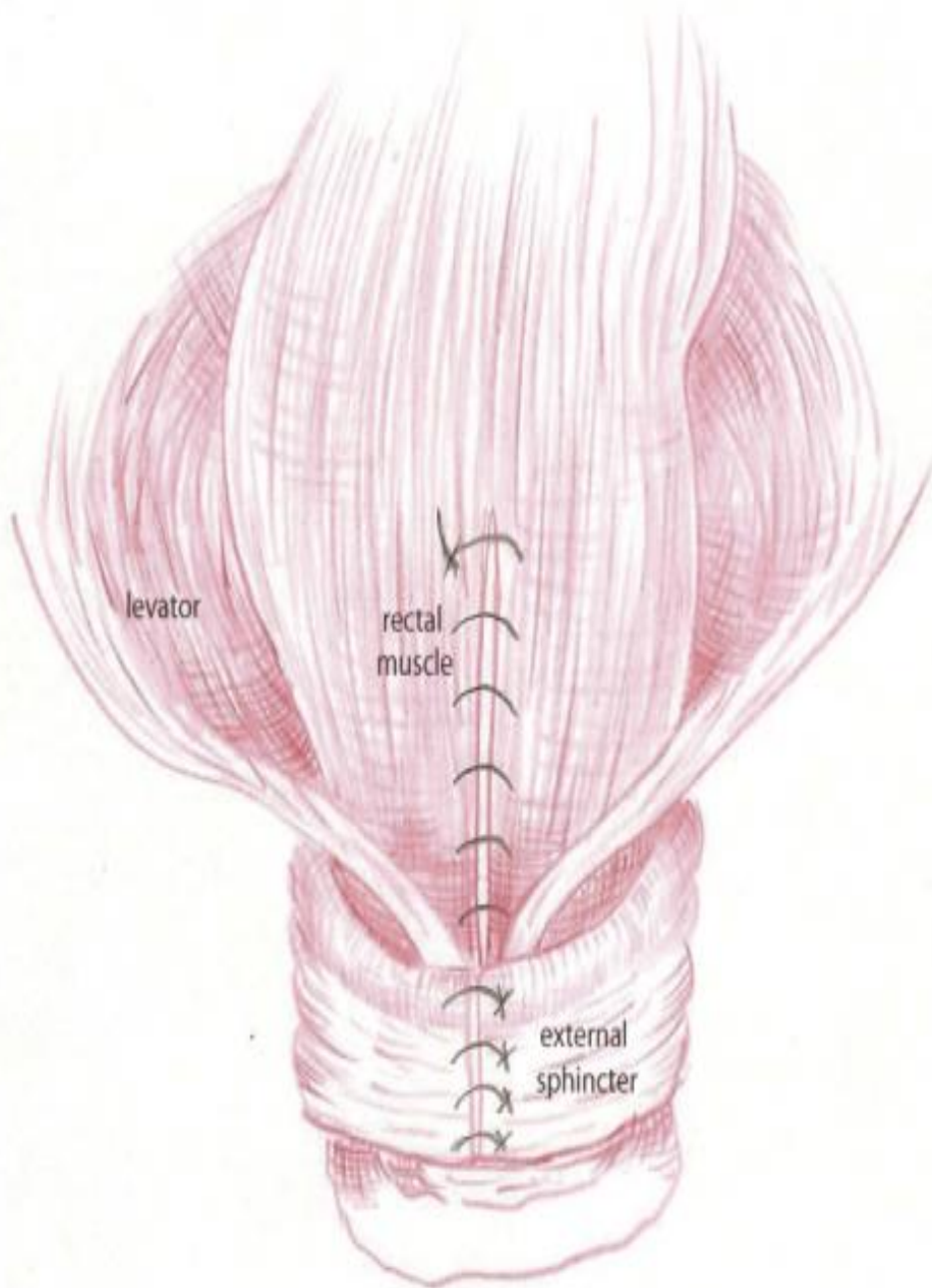
Sacrospinous fixation:

unilateral or bilateral fixation of the uterus to the sacrospinous ligament. Performed via vaginal route. Lower success rate than sacrohysteropexy. Risk of injury to pudendal nerve and vessels and sciatic nerve.

- **Surgery for rectocele/enterocele**

- **Posterior colporrhaphy:**

involves levator ani muscle plication or by repair of discrete fascial defects. A mesh can be used for additional support. Performed transvaginally. Levator plication may lead to dyspareunia.



- **Obliterative surgery**
- **Corrects prolapse by moving the pelvic viscera back into the pelvis and closing off the vaginal canal. Known as colpocleisis.**
- **Vaginal intercourse is no longer possible.**
- **Advantages are that it is almost 100% effective in treating prolapse and has a reduced perioperative morbidity.**
- **Not commonly carried out in Europe.**

Prevention:

- Possible preventative measures:
- Good intrapartum care:
 - including avoiding instrumental trauma and prolonged labour.
- Pelvic floor exercises may prevent prolapse so advised after childbirth.
- Smoking cessation.
- Weight loss if overweight or obese.
- Avoidance of heavy lifting occupations.
- Treatment of constipation throughout life.

Living With Prolapse:
One Woman's Journey
*Where there is hope there
is strength, where there is
strength there is healing.*

www.striveforprogress.com

