

The Endodontics

Anatomical consideration (pulp canal) of all teeth

**By: Thulficar Al-Khafaji
BDS, MSC, PhD**

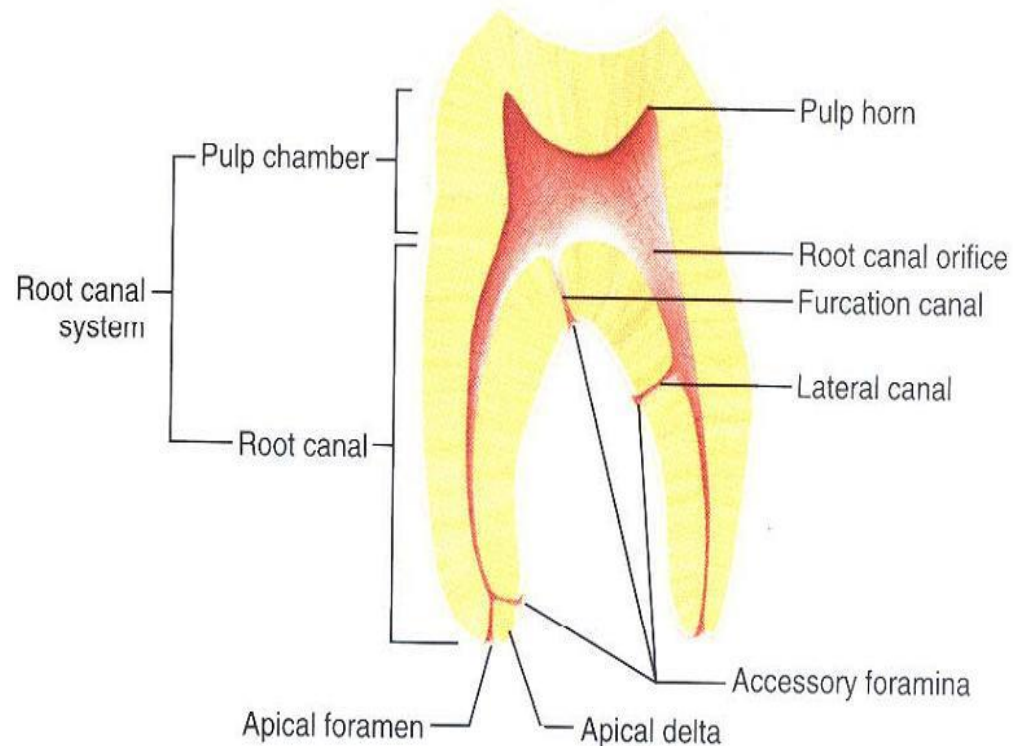
Root canal anatomy

The root canal usually starts as a funnel-shaped at canal orifice and terminates at the apical foramen.

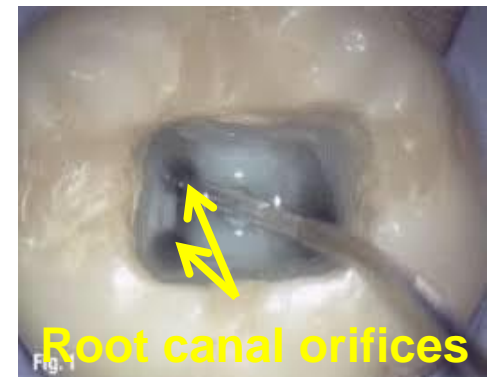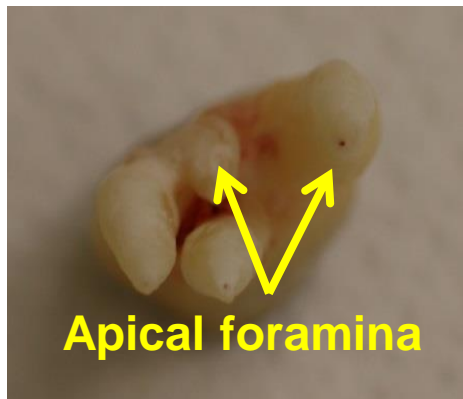
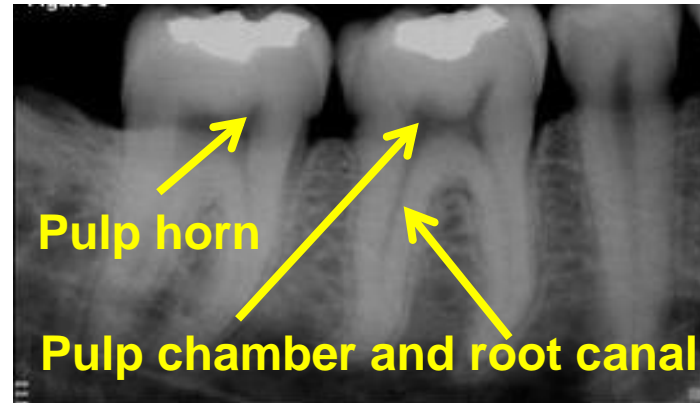
Normal anatomical features of the pulp space include:

- pulp chamber and root canal
- pulp horns
- root canal orifices
- apical foramina

It is important to understand the anatomical complexity of the spaces in which root canal infection could reside.

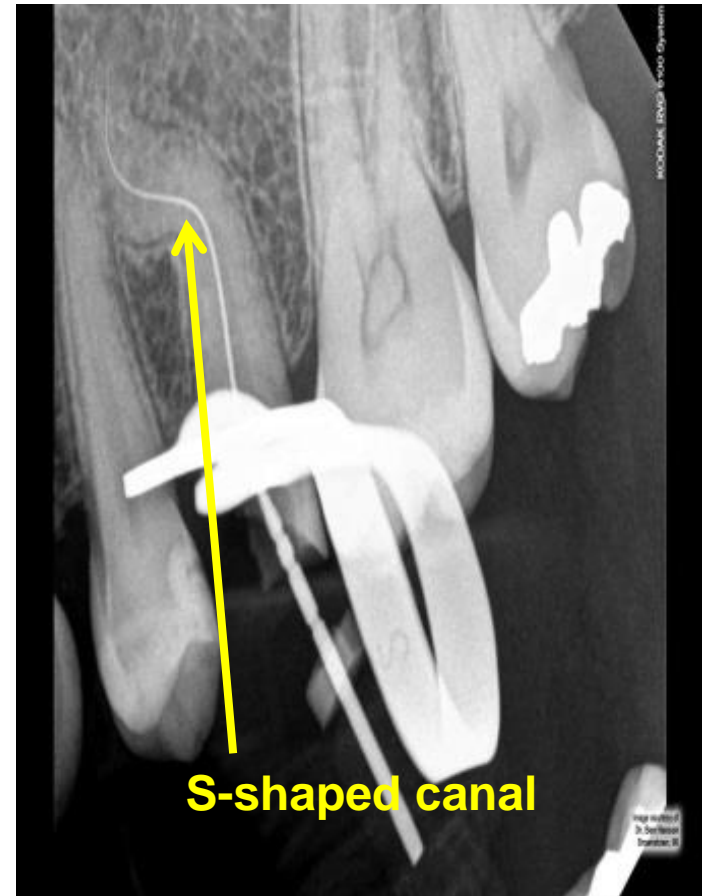


Root canal anatomy



Variations in the root canal anatomy

Nearly all of the root canals are curved, especially in facio-lingual direction. As a result, these curvatures could affect cleaning and shaping of the canals such as in S-shaped canals.



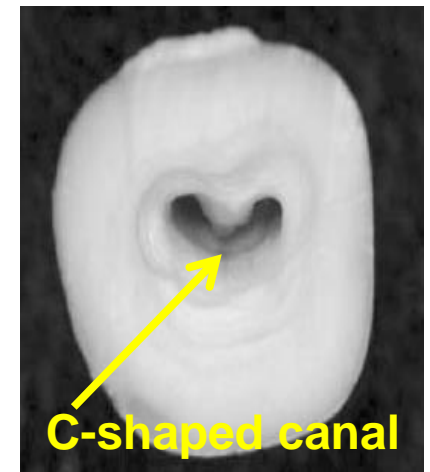
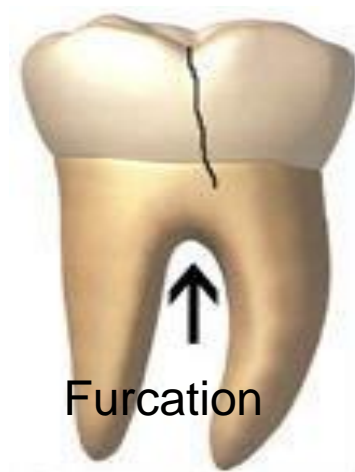
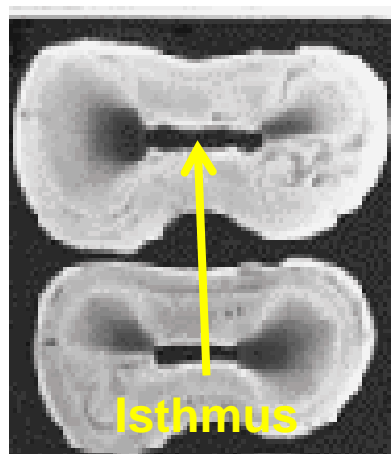
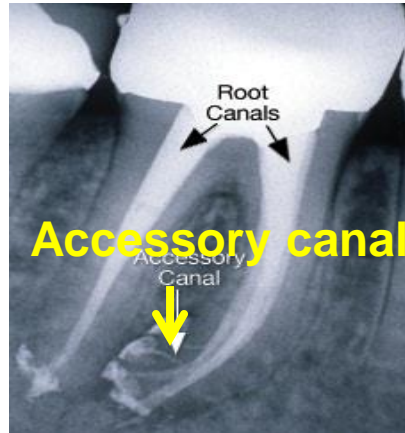
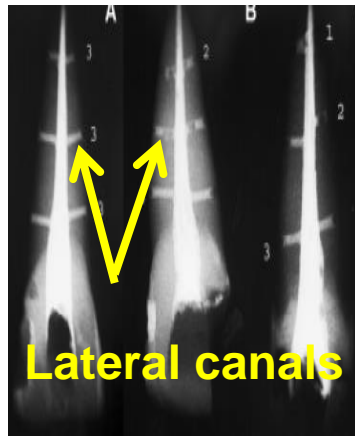
Variations in the root canal anatomy

Canal systems are, however, almost infinitely variable and can have:

- lateral canals
- additional canals
- multiple foramina
- accessory canals
- accessory foramina
- fins
- deltas
- loops
- web or internal connections (isthmuses between 2 canals)
- anastomoses
- root canal furcation (such as bi-furcation or tri-furcation, could be formed in multirooted teeth during the formation of pulp chamber floor by the entrapment of periodontal vessels)
- C-shaped canals or configurations.

Irregularities and aberrations in the root canals, such as hills and valleys in canal walls, internal communications (isthmuses between 2 canals), cul-de-sacs and fins, particularly in posterior teeth could be not accessible to instruments and/or irrigants.

Variations in the root canal anatomy

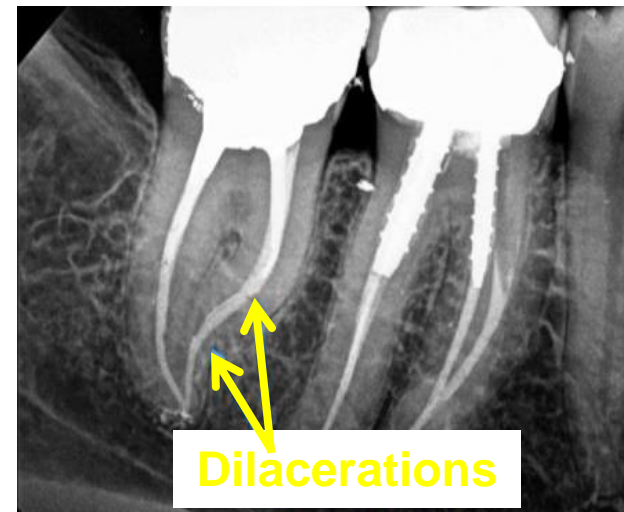
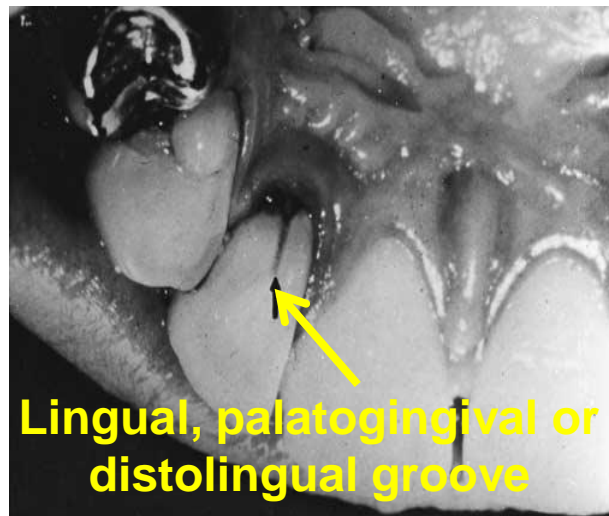
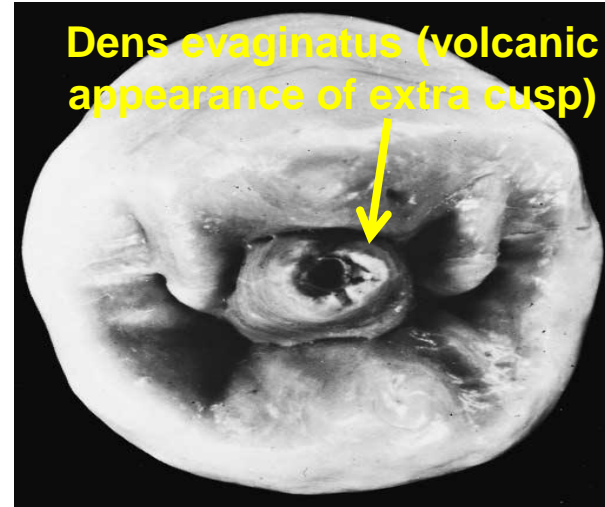
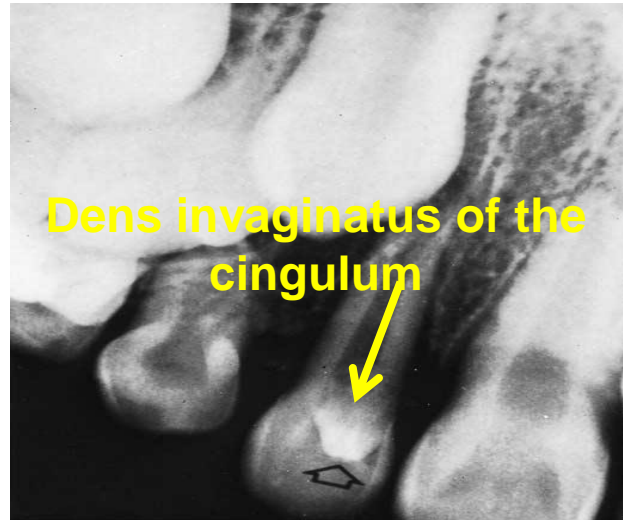


Other variations in the root canal anatomy

Other variations in pulp anatomy, which mostly happen in the maxillary lateral incisors, maxillary and mandibular premolars and maxillary molars such as:

- dens invaginatus (dens in dente)
- dens evaginatus
- lingual groove
- dilacerations
- high pulp horns

Other variations in the root canal anatomy



Causes of variations

Root canal anatomy can be changed by the deposition of :

- secondary
- tertiary dentine
- apical deposition of cementum.

Examples of factors which could change dimensions of pulp are:

- physiological ageing
- pathosis
- occlusion

All of this **highlights** the **complex**, often curved spaces in which **microorganisms** and their **substrate reside**. Therefore, this could be a **challenge** for cleaning, shaping and obturation of the canals.

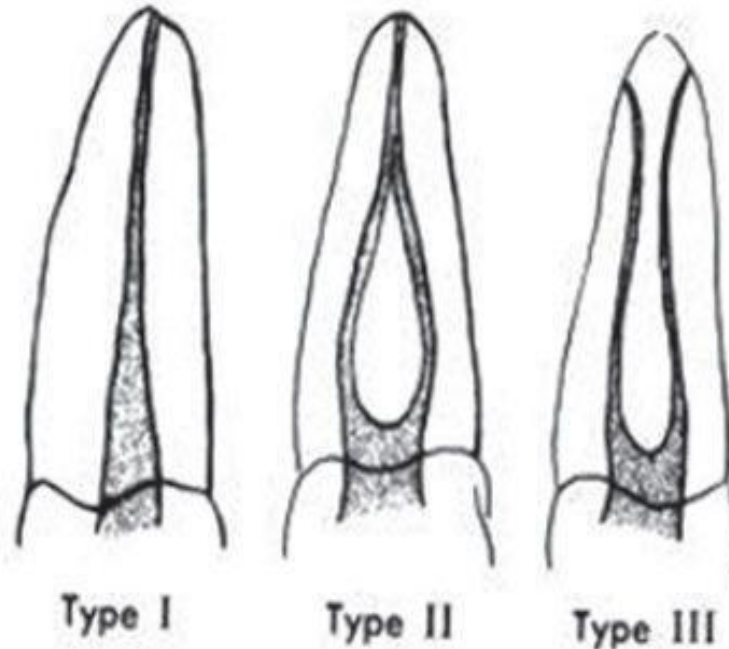
Classification of root canal system

Weine *et al* (1969) classified root canals systems into four basic types, but Vertucci *et al* (1984) subsequently classified them into eight configurations. The Vertucci *et al* (1984) classification may reflect the complex reality of canal systems, in a way that the Weine *et al* (1969) system did not.

Classification of root canal system

Weine's 4 basic forms are:

- Type I: A single root canal extend from the pulp chamber to the apex.
- Type II: Two separate root canals leave the pulp chamber and join short of the apex to form one canal.
- Type III: Two separate root canals leave the pulp chamber remain separate to the site of exiting.
- Type IV: Three separate and distinct root canals extend from the pulp chamber to the apex.



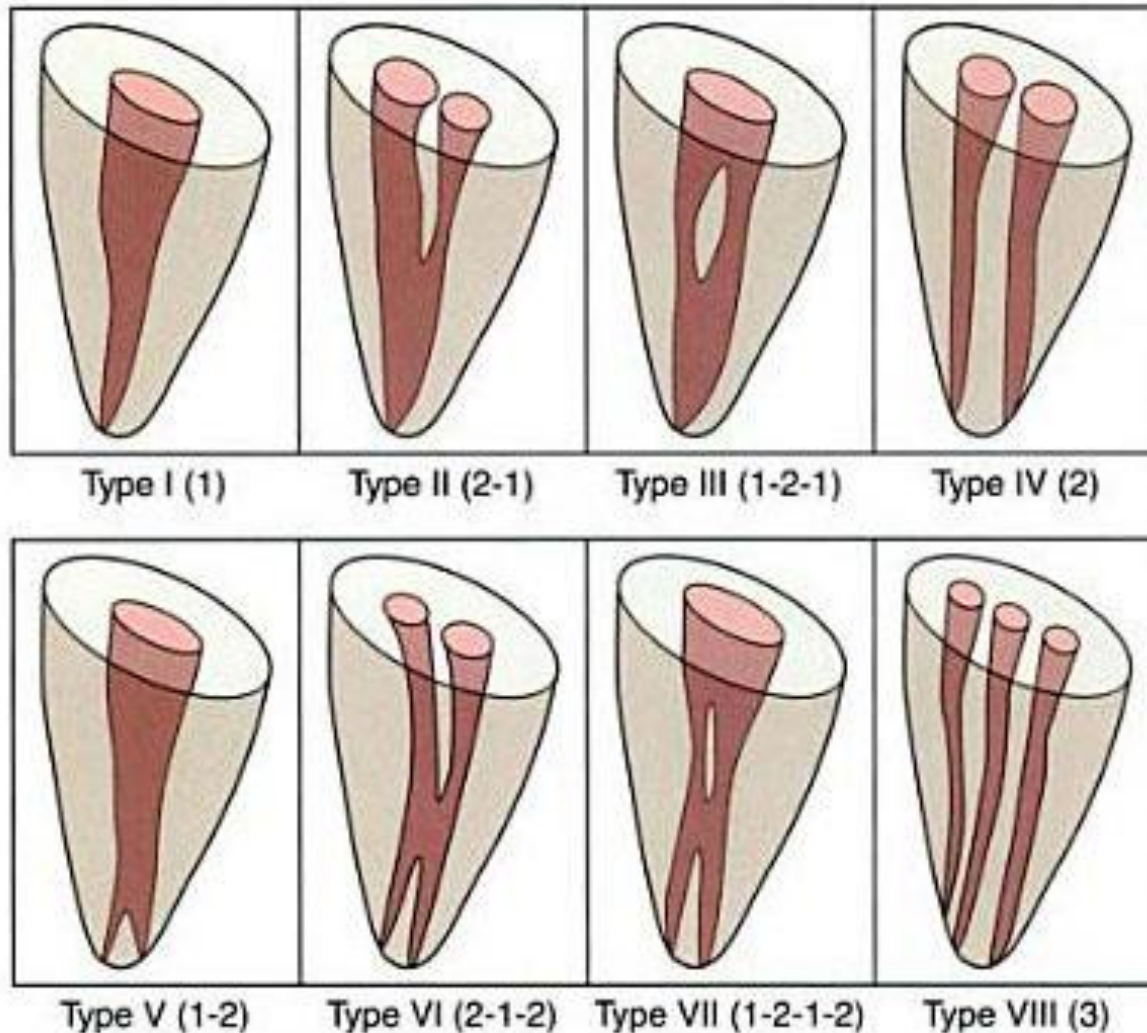
Weine's classification of root canal morphology.

Classification of root canal system

Vertucci's 8 basic forms are:

- Type I: A single canal extending from the pulp chamber to the apex.
- Type II: Two separate canals leaving the pulp chamber and joining short of the apex to form one canal.
- Type III: One canal leaving the pulp chamber and dividing into two in the root; the two then merge to exit as one canal.
- Type IV: Two separate, distinct canals extending from the pulp chamber to the apex.
- Type V: One canal leaving the pulp chamber and dividing short of the apex into two separate, distinct canals with separate apical foramina.
- Type VI: Two separate canals leaving the pulp chamber, merging in the body of the root, and re-dividing short of the apex to exit as two distinct canals.
- Type VII: One canal leaving the pulp chamber, dividing and re-joining in the body of the root, before and finally re-dividing into two distinct canals short of the apex.
- Type VIII: Three separate, distinct canals extending from the pulp chamber to the apex.

Classification of root canal system



Vertucci's classification of root canal morphology.

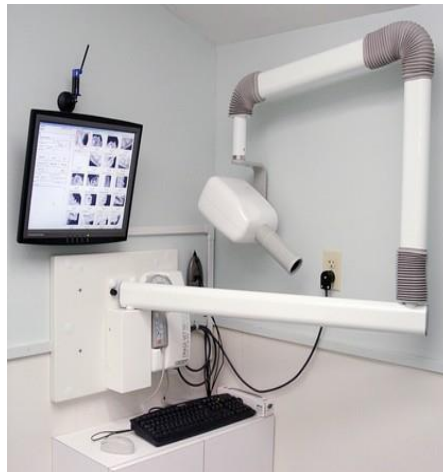Methods of determining root canal anatomy

There are **three** methods to help to know root canal **anatomy** which could result in successful root canal therapy.

- The first method is the textbook knowledge about the number of roots, the number of canals per root and their location. Moreover, it is about the longitudinal and cross-sectional shapes of the root canals, their most frequent curvatures, especially in the faciolingual direction, and root outlines in all dimensions.

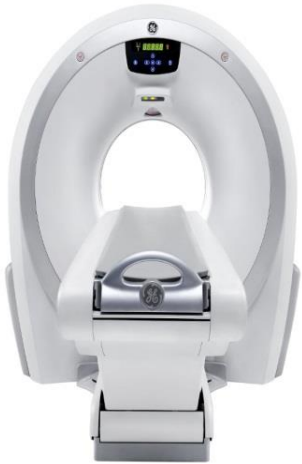Methods of determining root canal anatomy

- Secondly, the radiographic technique can show missed canals and curvatures, but in a two-dimensional image. Radiograph compresses three-dimensional anatomy into two-dimensional image or shadow which could limit diagnosis quality. Therefore, three-dimensional techniques have been suggested as adjuncts to conventional radiographs such as tuned aperture computed tomography “TACT”, magnetic resonance imaging “MRI”, ultrasound “US”, computed tomography “CT” and cone beam computed tomography “CBCT” .

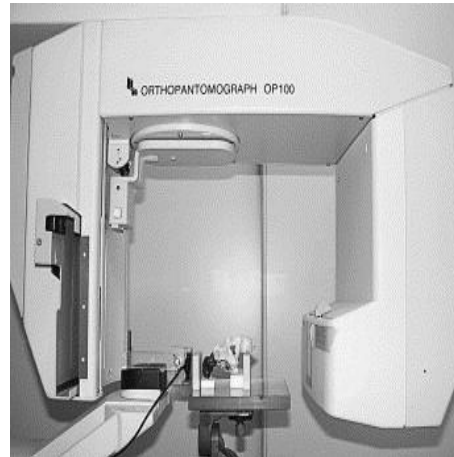


Dental x-ray machine

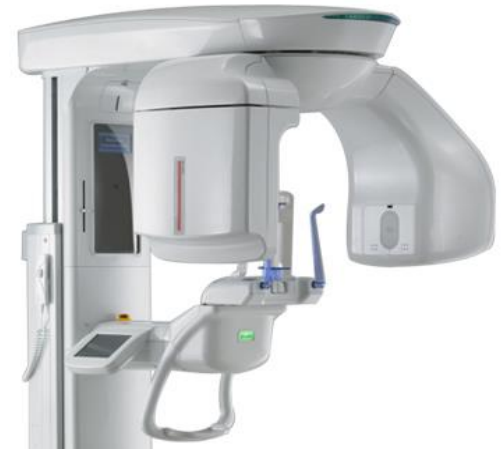Methods of determining root canal anatomy




Computed tomography "CT"



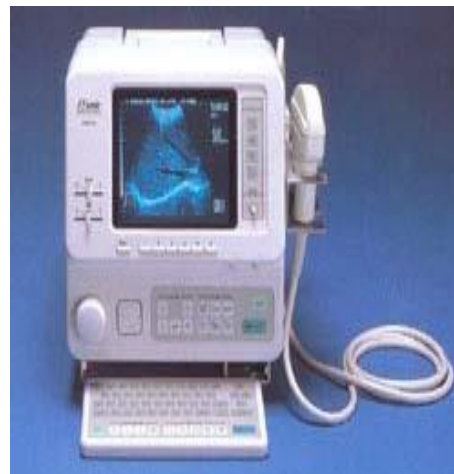Tune aperture computed tomography "TACT"



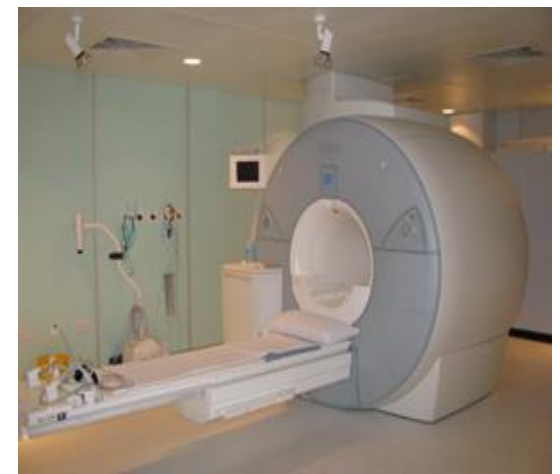Cone beam computed tomography "CBCT"



Micro-computed tomography



Ultrasound imaging
"US"



Magnetic resonance imaging "MRI"

Methods of determining root canal anatomy

- Finally, exploration is a supplementary method for obtaining knowledge about the canal after doing physical access into the pulp chamber, but it has some limitations in finding tiny canals.



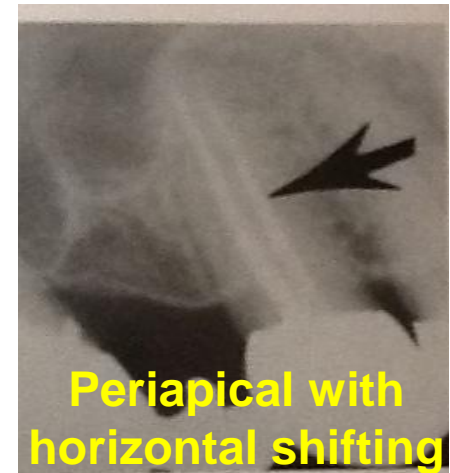
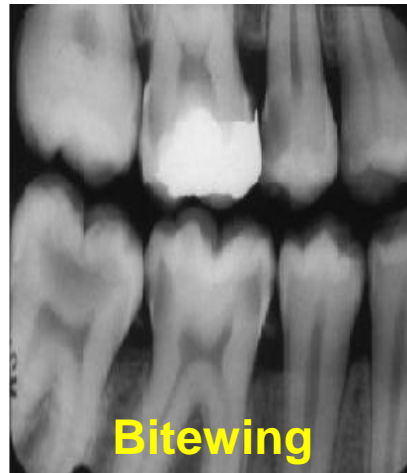
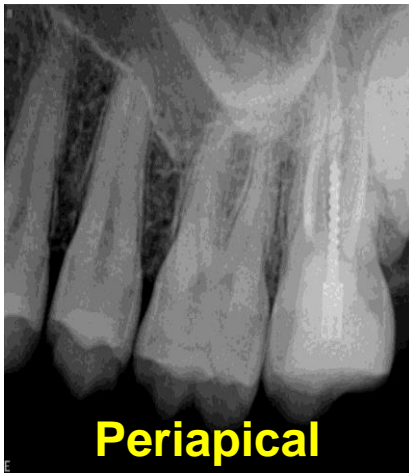Dental explorer

Root canal visualization in three dimensions

Root canal must be **visualized mentally** in **three dimensions** which could be achieved by

- pre-operative periapical radiograph
- relevant bitewing radiograph
- or another periapical radiograph at different horizontal angulation.

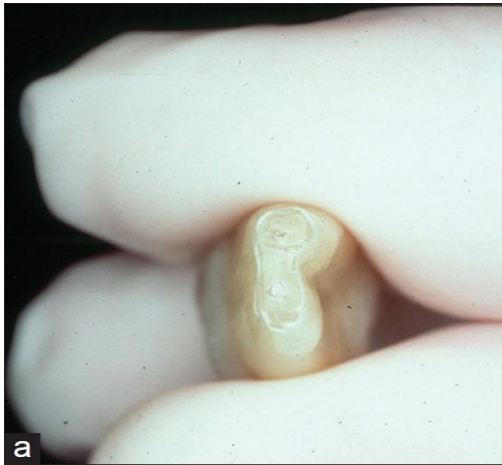So, the position, size, depth and shape of the pulp horns, number of roots and the degree of curvature can be assessed.



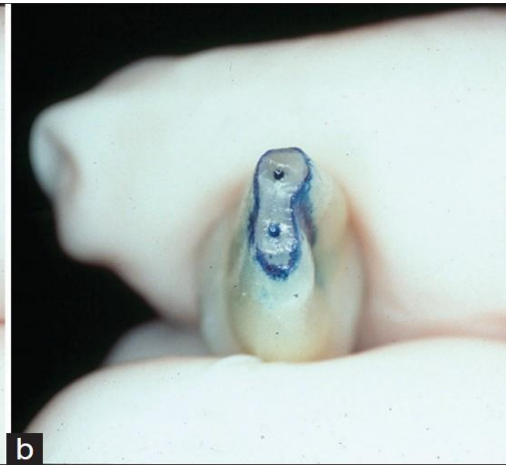
Location of root canal orifices

Diagnostic aids for **locating canal orifices** include:

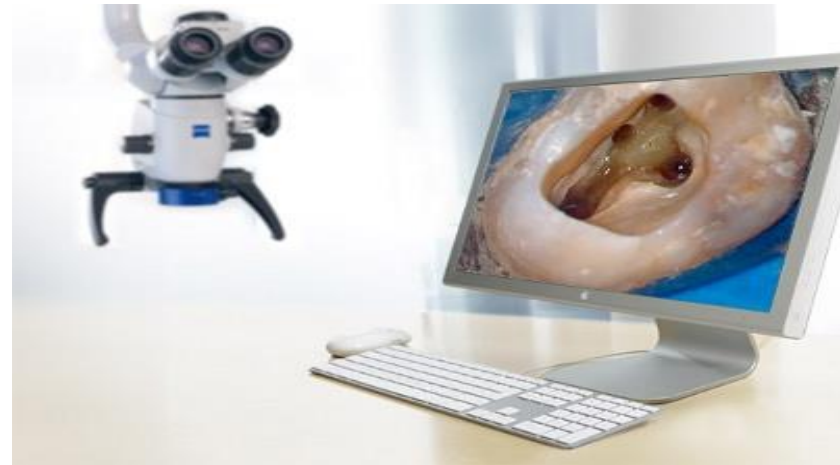- pre-treatment radiographs
- examining pulp chamber floor with a sharp explorer
- staining the pulp chamber with 1% methylene blue dye
- a key development in recent times is the adoption of the dental operating microscope for improved visibility, illumination and reduce procedural errors, which has been pioneered as an aid for endodontic diagnosis in 1970s



Apical foramina
before application of
methylene blue dye



Apical foramina after
application of
methylene blue dye



Dental operating or surgical
microscope

Notes:

- The pulp, under **normal conditions**, tends to form dentin evenly, **faciolingually** and **mesiodistally**. The **pulp** therefore tends to lie in the **centre** of the tooth, and it is called the pulp cavity or pulp space which is divided into two main parts, the **pulp chamber** and the **root canal**.
- **At** the time of **eruption**, the pulp chamber of a tooth **reflects the external form** of the enamel.
- Orban stated that the shape of the root canal, “to a large degree, conforms to the shape of the root. A **few** canals are **round** and **tapering**, but many are **elliptical**, **broad** and **thin**”. A curve at the end of the root means almost invariably that the canal follows this curve. Meyer stated that “roots that are **round** and **cone-shaped usually** contain only **one** canal, but roots that are **elliptical** and have **flat** or **concave** surfaces **more frequently** have **more** canals **than one**”.
- The **foramen can change** in **shape** and **location** because of functional influences on the tooth.

Thank you