

Dr.Nada Khazal K. Hendi

L5:

**4-Class: Sporozoa****A:Malaria (Plasmodium species)**

- a. *Plasmodium falciparum* causes malignant tertian malaria
- b. *P. malariae*: causes Quartan malaria
- c. *P. vivax*: causes benign tertian malaria
- d. *P. ovale*: causes benign tertian malaria

Malaria is an acute infectious disease of the blood, caused by one of four species of the protozoal genus, *P. falciparum* accounts for some fifteen percent of all malaria cases, and *P. vivax* for Eighty percent of malarial cases.

The plasmodial parasite is transmitted to humans through the bite of a female *Anopheles* mosquito, or by an infected, blood-contaminated, needle.

Sporozoans reproduce asexually in human cells by a process called schizogony, in which multiple nuclear divisions are followed by envelopment of the nuclei by cell walls. DE3WSXreproduction occurs in the mosquito, where new spores (sporozoites) are formed process called sporogony. **Schizogony (asexually in human; intermediated host), sporogony (Sexual reproduction in the mosquito; definitive host).**

Appearance of infected RBCs	Enlarged , distorted
Ring form	Delicate cytoplasmic ring measuring 1/3 RBC diameter Single chromatin dot, Ring surrounds a vacuole
Developing trophozoite	Irregular ameboid appearance Ring remnants common Brown pigment
Immature schizont	Multiple chromatin bodies Brown pigment
Mature schizont	12 to 24 merozoites occupying majority of the RBCs Merozoites surrounded by cytoplasmic material Brown pigment may be present
Microgametocyte	Large pink to purple chromatin mass surrounded by colorless to pale halo
Macrogametocyte	Round to oval cytoplasm , Eccentric chromatin mass Delicate light – brown pigment present throughout cell

**Pathology and clinical significance:**

Plasmodium sporozoites are injected into the bloodstream, where they rapidly migrate to the liver. There they form cyst-like structures containing thousands of merozoites. Upon release, the merozoites invade red blood cells, using hemoglobin as a nutrient. Eventually, the infected red cells rupture, releasing merozoites that can invade other erythrocytes. If large numbers of red cells rupture at roughly the same time, a paroxysm (sudden onset) of fever can result from the massive release of toxic substances.

Plasmodium falciparum is the most dangerous plasmodial species. It can cause a rapidly fulminating disease, characterized by persistent high fever and orthostatic hypotension. Infection can lead to capillary obstruction and death if treatment is not prompt. *P. malariae*, *P. vivax*, and *P. ovale* cause milder forms of the disease, probably because they invade either young or old red cells, but not both. This is in contrast to *P. falciparum*, which invades cells of all ages. Even today, malarial infection is a common and serious disease, causing some 300 million cases per year, with a death rate of about one percent.

***Clinical symptoms***

**Benign Tertian Malaria.** Patients infected with *P. vivax* typically begin to develop symptoms following a 10 to 17 day incubation period following exposure. These vague symptoms mimic those usually seen in cases of the flu, including nausea, vomiting, headache, muscle pains, and photophobia .

As infected RBCs begin to rupture, the resulting merozoites, hemoglobin, and toxic cellular waste products initiate the first in a series of paroxysms. These paroxysms typically occur every 48 hours.

**Life cycle**

Members of the mosquito genus *Anopheles* are responsible for the transmission of malaria to humans via a blood meal. These vector transfers malarial **sporozoites** from its salivary

**Dr.Nada Khazal K. Hendi**

gland into the human wound. Following entrance into the body, the sporozoites are carried through the peripheral blood to the parenchymal cells of the liver. It is here where **schizogony** occurs. This **exoerythrocytic cycle** of growth and reproduction lasts from 8 to 25 days, depending on the specific *Plasmodium* species involved. The infected liver cells eventually rupture and introduce merozoites into the circulating blood.

These migrating merozoites target age and – size – specific RBCs to invade, and upon doing so initiate the **erythrocytic cycle** of growth .it is in this asexual phase that the plasmodia feed on hemoglobin and pass through the numerous stages of growth, including the six morphologic forms previously described. Upon formation of the merozoites, one of three paths may take place. Some of the RBCs infected with merozoites rupture, releasing these forms to target and infect new RBCs, and this part of the cycle repeats itself. Numerous erythrocytic cycles may occur. However, other infected RBCs containing merozoites develop into microgametocytes and macrogametocytes. Still others are destroyed by the immune system of otherwise healthy individual.

Transmission of malaria back into the vector occur when the mosquito ingests mature male (micro) and female (macro) **gametocytes** during a blood meal, thus initiating the sexual cycle of growth. a male and female gametocyte unite in the mosquito's stomach and form a zygote matures into an oocyst . upon complete maturation , the oocyst ruptures and releases numerous sporozoites , which migrate into salivary gland of the mosquito and are ready to infect another unsuspecting human . Thus the cycle repeats itself.

**Drug treatment** depends on the stage of infection. Primaquine is effective against the exoerythrocytic forms in the liver and bloodstream and also against the gametocytic form, but inactive against parasites in red blood cells. Therefore, for the erythrocytic form, primaquine is administered in conjunction with a blood schizontocide such as chloroquine,

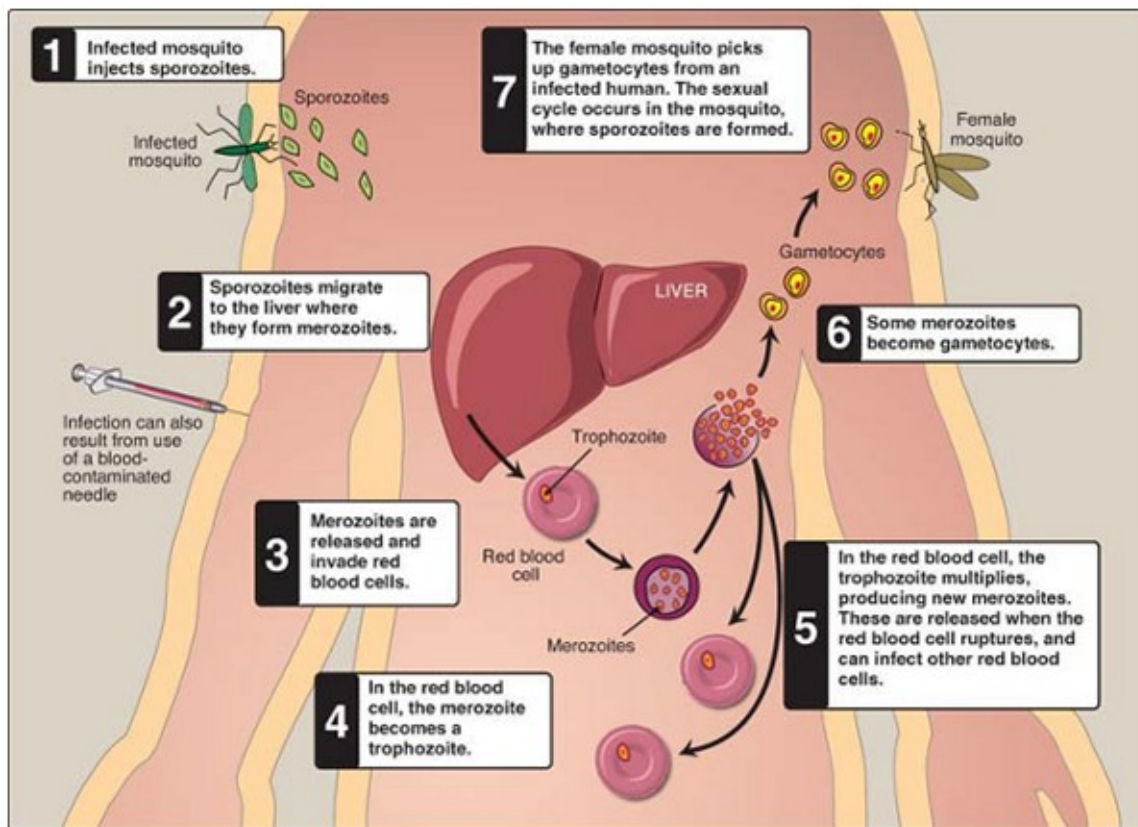


Fig. (1) : *Plasmodium vivax* life cycle .

**B: Toxoplasmosis (*Toxoplasma gondii*)**

*Toxoplasma gondii* is a sporozoan, distributed worldwide, that infects all vertebrate species, although the definitive host is the cat. Humans can become infected by the accidental ingestion of oocysts present in cat feces, by eating raw or undercooked meat, congenitally from an infected mother, or from a blood transfusion.

Table ( 2 ): <i>Toxoplasma gondii</i> oocyst : Typical characteristics	
Size range	25 to 35 μm long , 10 to 15 μm wide
Appearance	Transparent
Shape	Oval
Other features	<b>Young oocyst</b> contains two sporoblasts. <b>Mature oocyst</b> contains two sporocysts, each containing four sporozoites.

**Dr.Nada Khazal K. Hendi**

General comment	Actively multiplying morphologic form
Size	3 to 7 $\mu\text{m}$ by 2 to 4 $\mu\text{m}$
Shape	Crescent shaped , often more rounded one end
Number of nuclei	One
Other features	Contains a variety of organelles that are not readily visible

General comment	Slow - growing morphologic form
Size	Smaller than tachyzoites
Physical appearance	Similar to that of the tachyzoites
Number of nuclei	One
Other features	Hundreds to thousands of bradyzoites enclose themselves to form a cyst that may measure 12 to 100 $\mu\text{m}$ in diameter

**Pathology and clinical significance:**

There are two kinds of *Toxoplasma* trophozoites found in human infections: rapidly growing tachyzoites (tachy = rapid) that are seen in body fluids in early, acute infections, and slowly growing bradyzoites (brady = slow) that are contained in cysts in muscle and brain tissue and in the eye. Tachyzoites directly destroy cells, particularly parenchymal and reticuloendothelial cells, whereas bradyzoites released from ruptured tissue cysts cause local inflammation with blockage of blood vessels and necrosis. Infections of normal human hosts are common and usually asymptomatic. However, they can be very severe in

**Dr.Nada Khazal K. Hendi**

immunocompromised individuals, who may also suffer recrudescence (relapse) of the infection. Congenital infections can also be severe, resulting in stillbirths, brain lesions, and hydrocephaly and they are a major cause of blindness in newborns.

**Life cycle**

The definitive host in the *Toxoplasma* life cycle is the cat (or other felines). Upon ingestion of *Toxoplasma* cysts present in the brain or muscle tissue of contaminated mice or rats, the enclosed bradyzoites are released in the cat and quickly transform into tachyzoites. Both sexual and asexual reproduction occurs in the gut of the cat. The sexual cycle results in the production of immature oocysts, which are ultimately shed in the stool. The oocysts complete their maturation in the outside environment, a process that typically takes from 1 to 5 days. Rodents, particularly mice and rats, serve as the intermediate hosts, ingesting the infected mature *Toxoplasma* oocysts while foraging for food. The sporozoites emerge from the mature oocyst and rapidly convert into actively growing tachyzoites in the intestinal epithelium of the rodent.

**Clinical symptoms**

**Toxoplasmosis** a common infection with the protozoan intracellular parasite *Toxoplasma gondii*. It is marked in its inborn form by liver and brain involvement with calcium in the brain (cerebral calcification), convulsions, blindness, too-small head and fluid on the brain (microcephaly and hydrocephaly), and mental retardation. The acquired form is marked by rash, disease of the lymph nodes (lymphadenopathy), fever, malaise, central nervous system disorders, swelling of the heart wall (myocarditis), and swelling of lung tissue (pneumonitis). Cats acquire the organism by eating infected birds and mice. Lumps (cysts) of the organism are carried from cat feces to humans or by human ingestion of inadequately cooked meat containing the lumps. Infection through the placenta occurs only during acute infection of the mother. The other route of human infection occurs when contaminated blood is transfused into an uninfected person.

**Diagnosis and treatment:**

The initial diagnostic approach involves detection of parasites in tissue specimens, but this may often be inconclusive. With the recent availability of commercial diagnostic kits, serologic tests to identify toxoplasma are now routinely used. These include tests for

Dr.Nada Khazal K. Hendi

Toxoplasma-specific IgG and IgM. The treatment of choice for this infection is the antifolate drug pyrimethamine, given in combination with sulfadiazine.

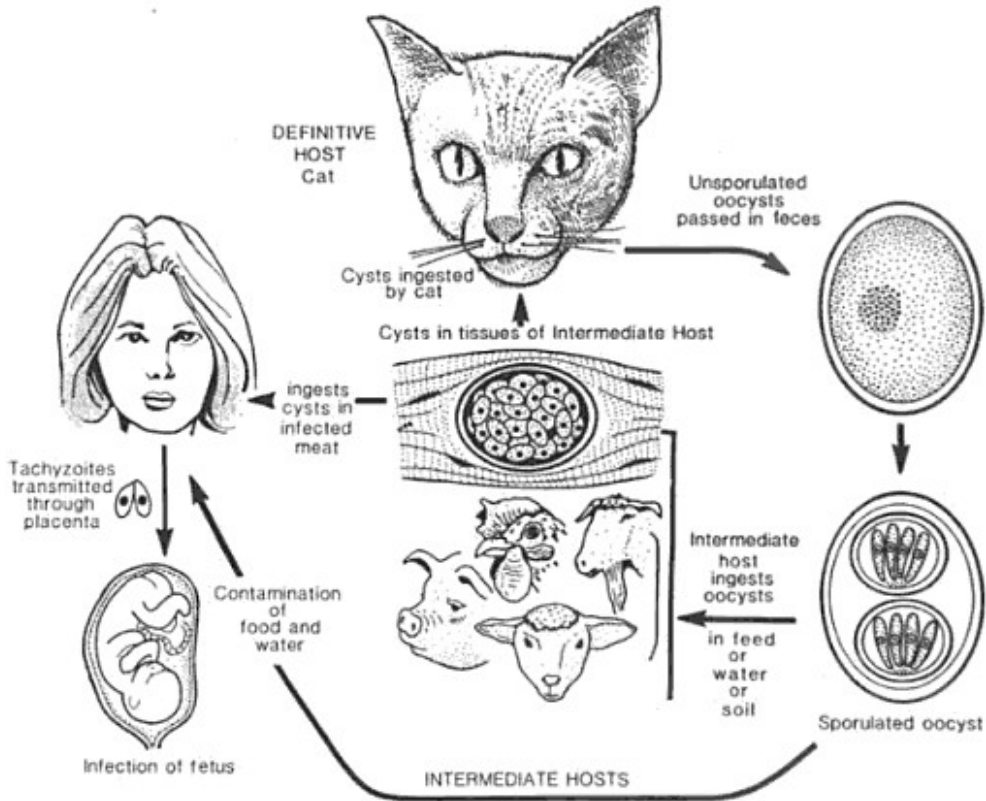


Figure 1.1 Life cycle of *Toxoplasma gondii*.