

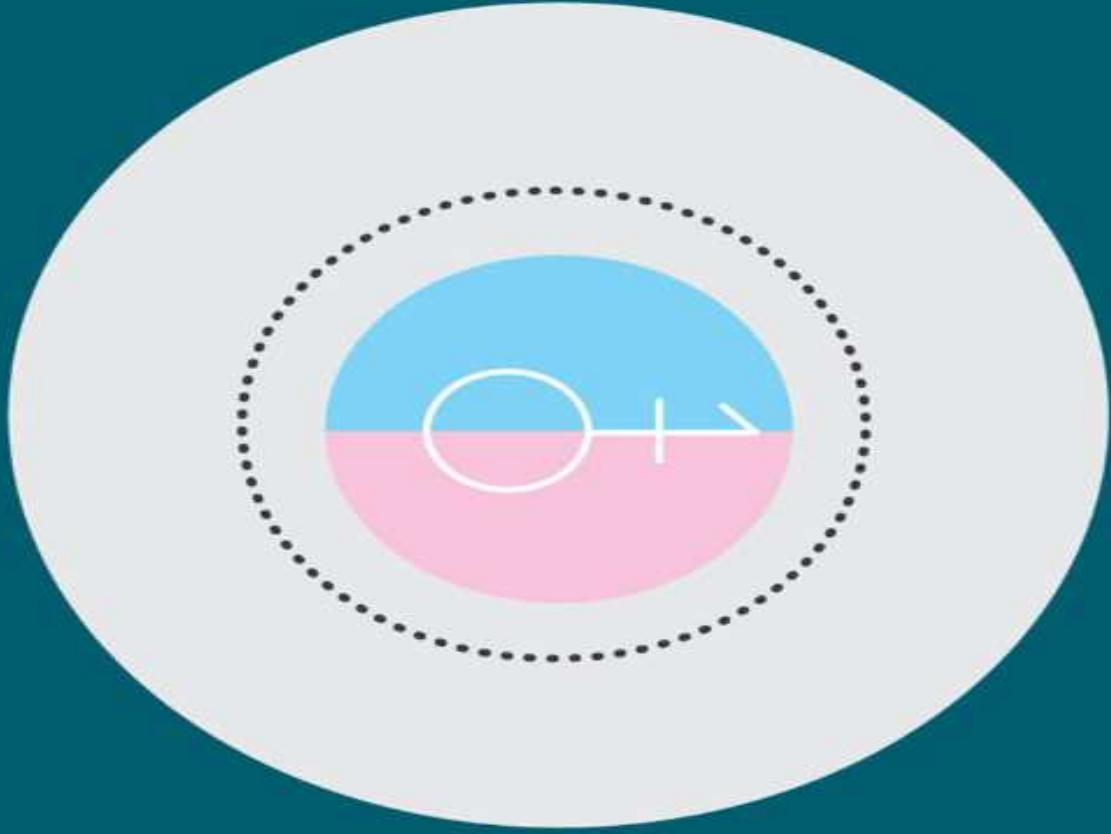
Disorder of sexual development & mullerian abnormality

Summary of Normal Sex Differentiation

- genetic sex is determined at fertilization.
- testes develop in XY fetus, ovaries develop in XX fetus.
- XY fetus produces MIS and androgens and XX fetus does not.
- XY fetus develops Wolffian ducts and XX fetus develops Mullerian ducts.
- XY fetus masculinizes the female genitalia to make it male and the XX fetus retains female genitalia.

INTERSEX

Describes a condition in which a person is born with a sex that doesn't fit the typical definitions of female or male due to genetic, hormonal or anatomical differences.



Intersex (DSD)

Normal karyotype

XY female

XX male ?? (ambiguous genitalia)

Abnormal karyotype

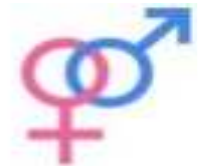Turner syndrome XO

True hermaphroditism (XX ,XY)

Additional sex chromosomes

(XXX ,XXY)

XY FEMALE



46,XY DSD

- 1) Defects in Testicular Development
 - a) Denys-Drash syndrome
 - b) WAGR syndrome
 - c) XY pure gonadal dysgenesis (Swyer syndrome)
- 2) Deficiency of Testicular Hormones
 - a) Leydig cell aplasia
 - b) Lipoid adrenal hyperplasia deficiency;
 - c) 3β -HSD II deficiency
 - d) 17-Hydroxylase/17,20-lyase deficiency
- 3) Defect in Androgen Action
 - a) 5α -reductase II deficiency
 - b) Androgen insensitivity syndrome(AIS)

Presentation

Primary amenorrhea

Well developed female body image

Absence of pubic and axillary hair in case of androgen insensitivity

Inguinal hernia (gonades)

Primary infertility

Investigation

Karyotype study

Imaging (ultrasound ,CT ,MRI)

Hormonal assay

Management

Socially determined

Sex diversion + HRT

Gonadectomy to avoid cancer

Ambiguous Genitalia

(Hermaphroditism)

Definition –

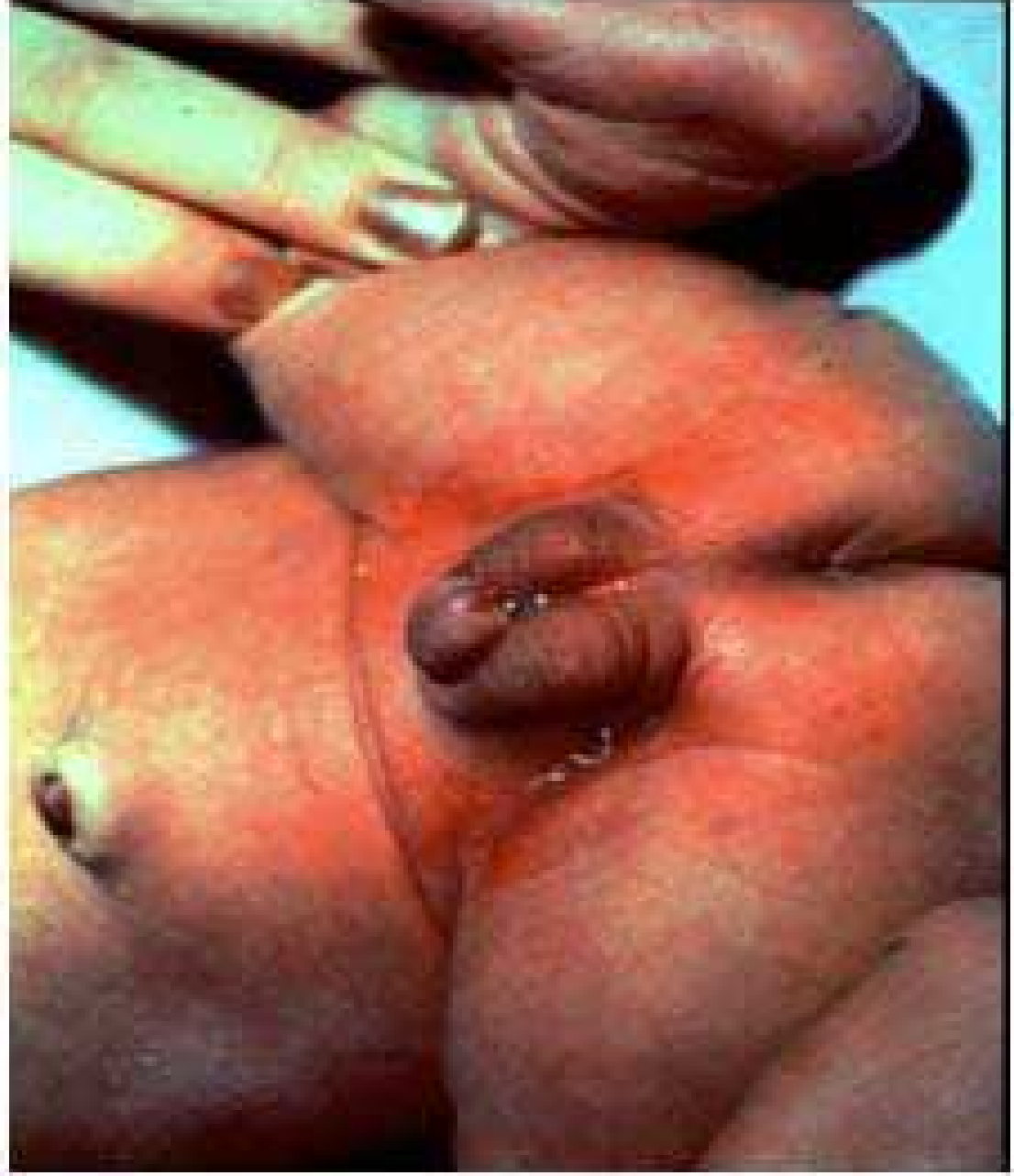The term ambiguous genitalia applies to any confusing appearance of the external genitalia. This includes any infant with

- 1 A phallus but bilaterally unpalpable testes
- 2 Unilateral cryptorchidism and hypospadias
- 3 Penoscrotal or perineoscrotal hypospadias , even if the testes are descended

Normal full-term male infant – Phallus at least 2.5 cm long

Normal full-term female infant – Clitoris less than 1cm ,
No posterior labial fusion

Increased androgen production results in ambiguous genitalia in newborn girls.



Ambiguous genitalia

XX female exposed to androgen which result in virilization and masculinization of female fetus this is called pseudohermaphroditism

Androgen source either :

- Endogenous as CAH ,ovarian ,adrenal tumour
- Exogenous due to maternal ingestion of androgenic drugs during pregnancy

Congenital Adrenal Hyperplasia

CAH

Autosomal recessive inheritance

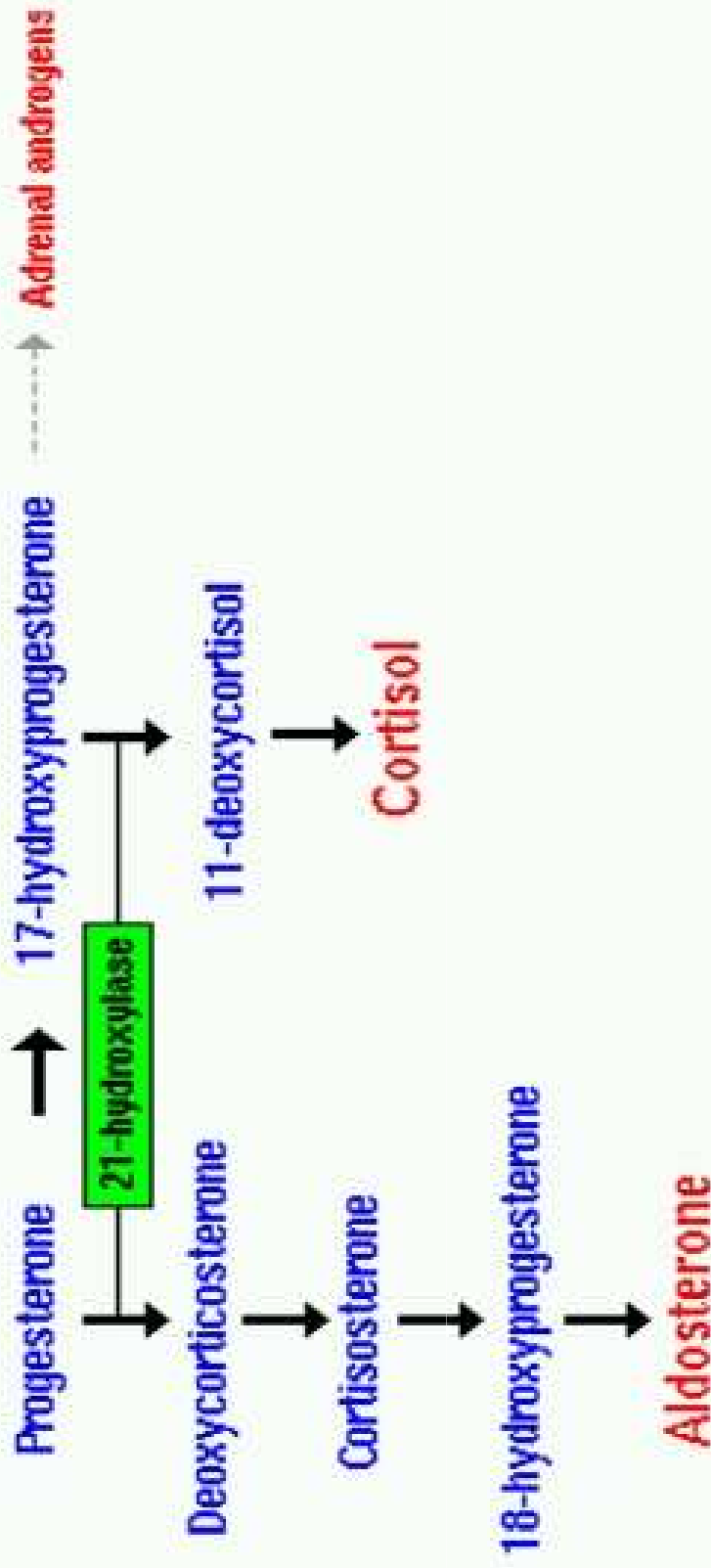
Due to enzyme deficiency in steroid pathway of adrenal gland

Of 2 types

- salt wasting type
- non salt wasting type

Result in decrease in cortisone ,aldosterone and excess androgen production

Normal pathway of adrenal steroid synthesis

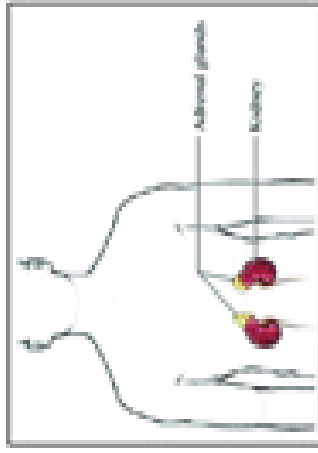


21-hydroxylase deficiency (absolute)



CONGENITAL ADRENAL HYPERPLASIA (CAH)

Normal Adrenal Gland

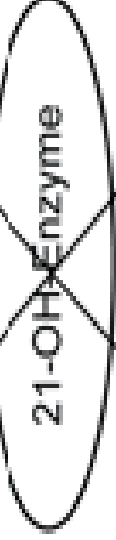
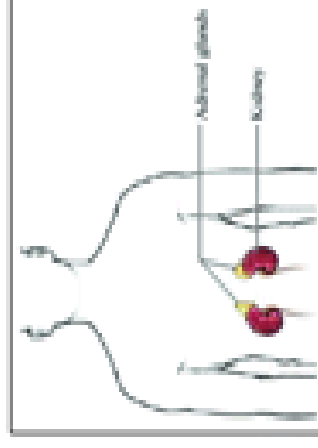

Normal amount of
Cortisol, Aldosterone
and Androgen hormones



Normal Health and Sexual
Development

Adrenal Gland in CAH



Decreased Cortisol
and Aldosterone



Multiple Health
Problems



Increased
Androgens



Genital Changes,
Early Puberty

Presentation of CAH

Early onset

ambiguous genitalia +/- salt losing enteropathy

Late onset

precocious puberty
virilization ,
amenorrhea and
infertility

Investigations

Hormonal and enzyme assay

Karyotype study

Imaging

Electrolyte

Treatment

Replacement therapy of deficient hormones

- steroid
- mineralocorticoid

Corrective surgery for genitalia

- success depend on severity
- Timing of surgery ??
- Result in scarring
- Sexual dysfunction

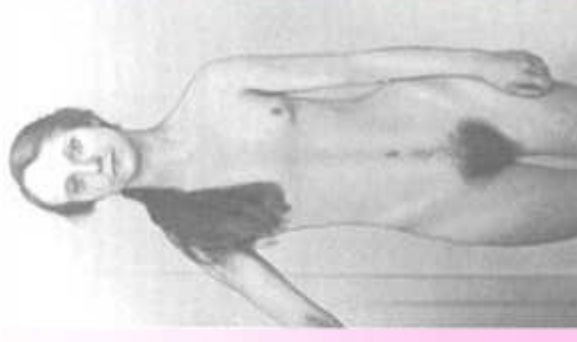
True Hermaphroditism

- Both ovarian and testicular tissue are present in the same individual
 - ovary on one side, testis on the other
 - “ovotestes”

- Uncommon

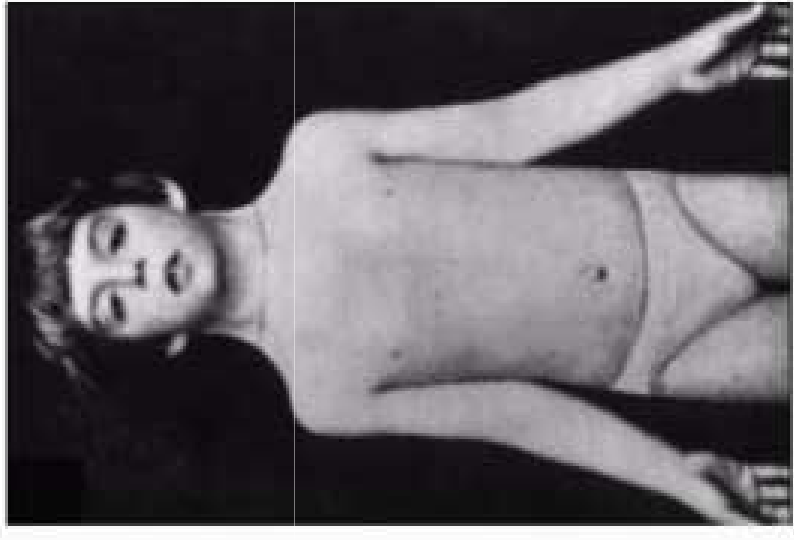
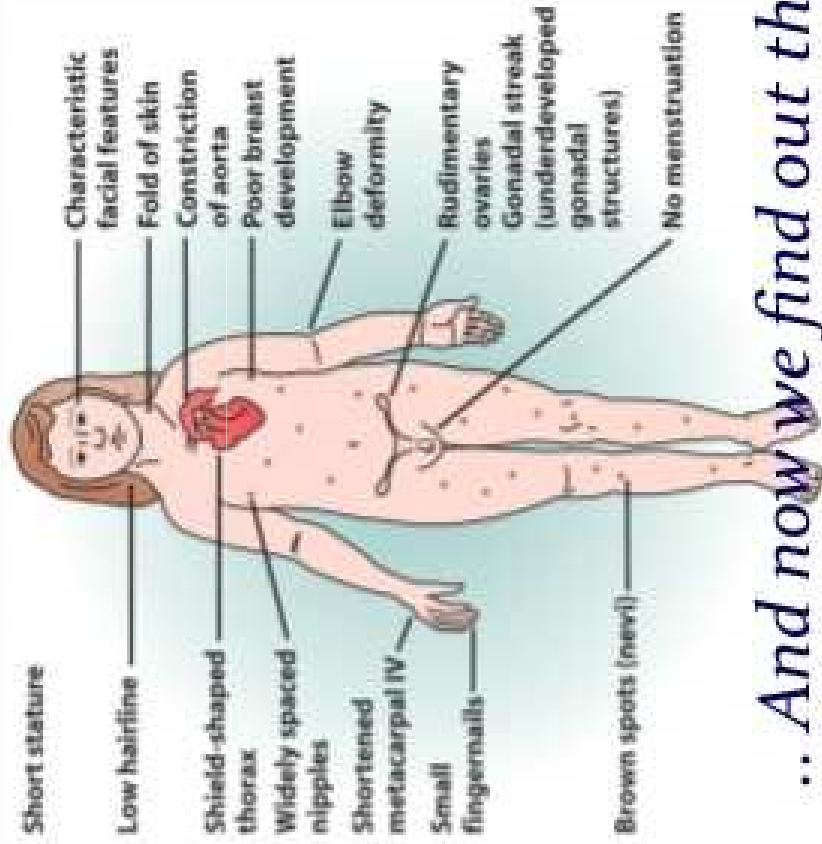
- Usually 46,XX; sometimes 46,XX/46,XY chimerism or mosaicism

- Phenotypically variable
- Some are fertile as females



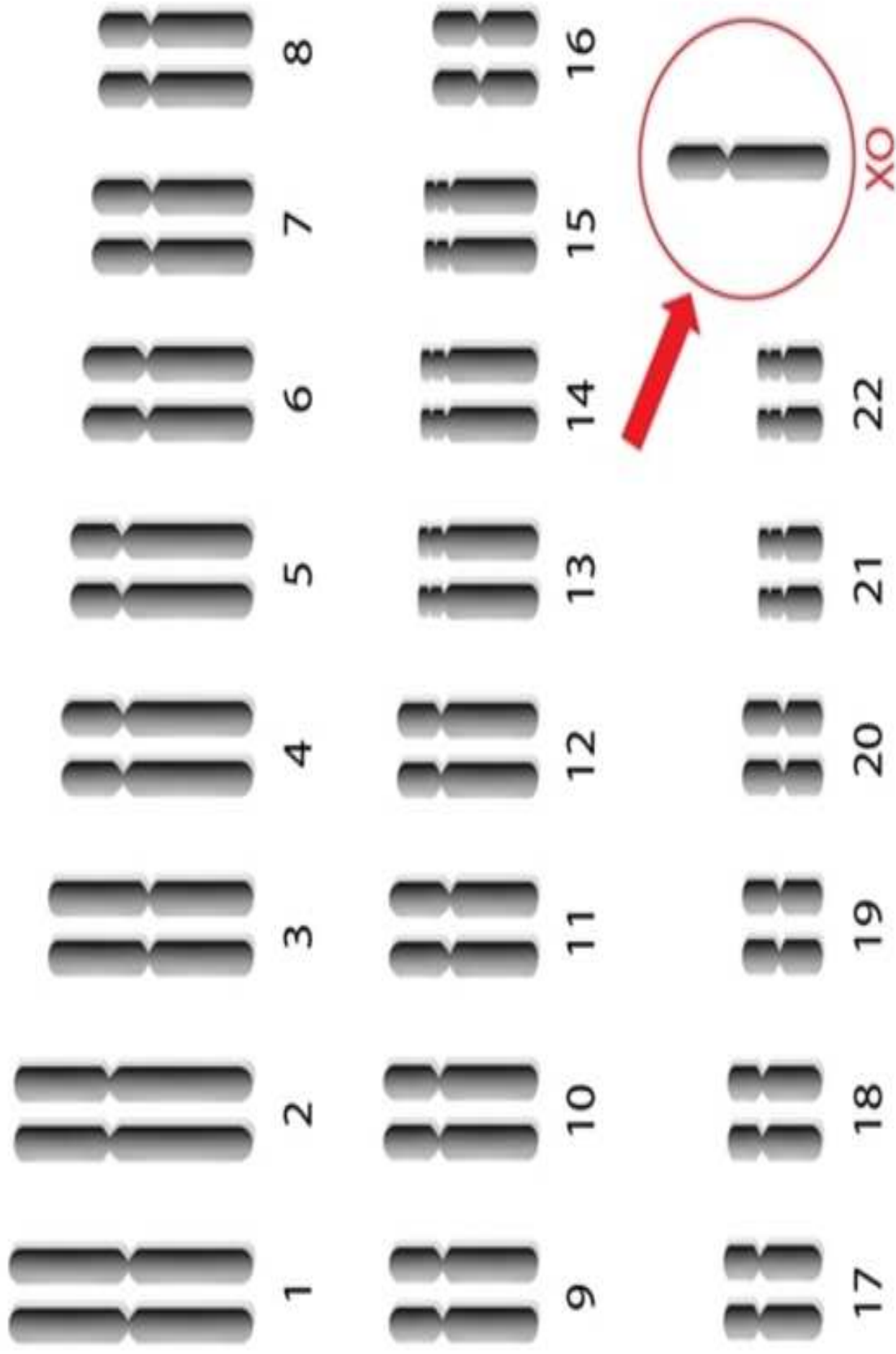
Turner Syndrome

Only one fully functional X



.. And now we find out there are females who lack sex-determining chromosome..

Turner's Syndrome

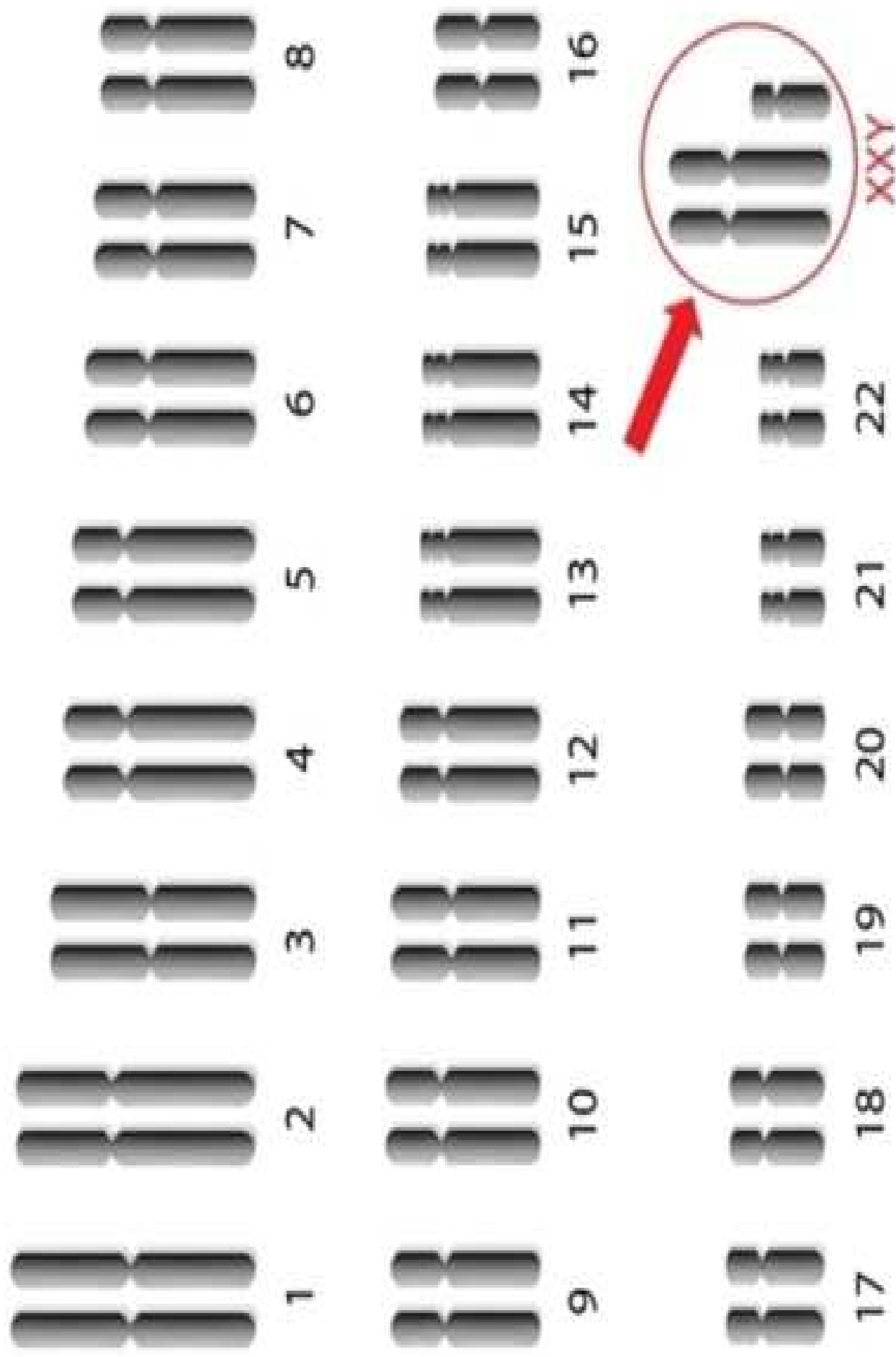


Kline Felter Syndrome.



- Kline Felter Syndrome is a genetic disorder that gives an extra X so the person with it will have sex chromosomes that are XXY in most cases. In some cases they have more than 2 X's.

Klinefelter Syndrome



Tall stature

Slightly feminized physique

Mildly impaired IQ

Tendency to lose chest hairs

Female-type pubic hair pattern

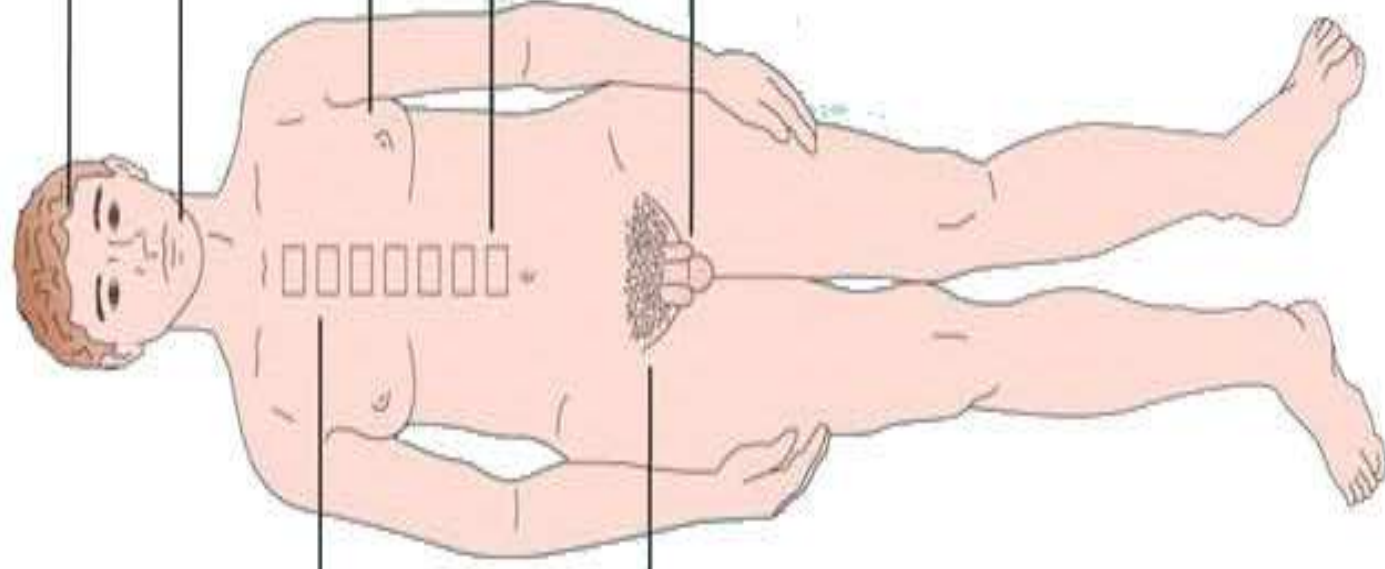
Frontal baldness absent

Poor beard growth

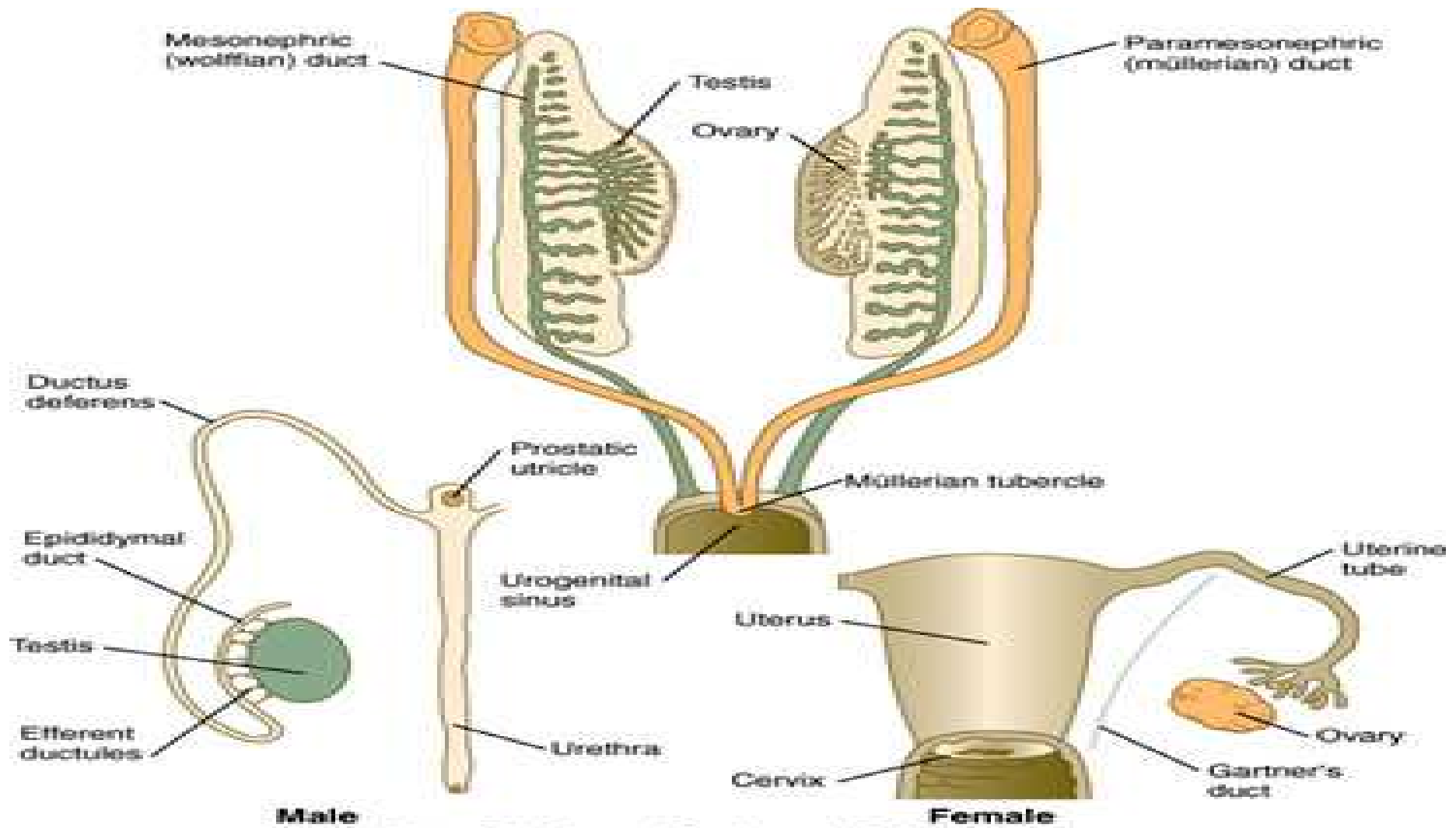
Breast development

Osteoporosis

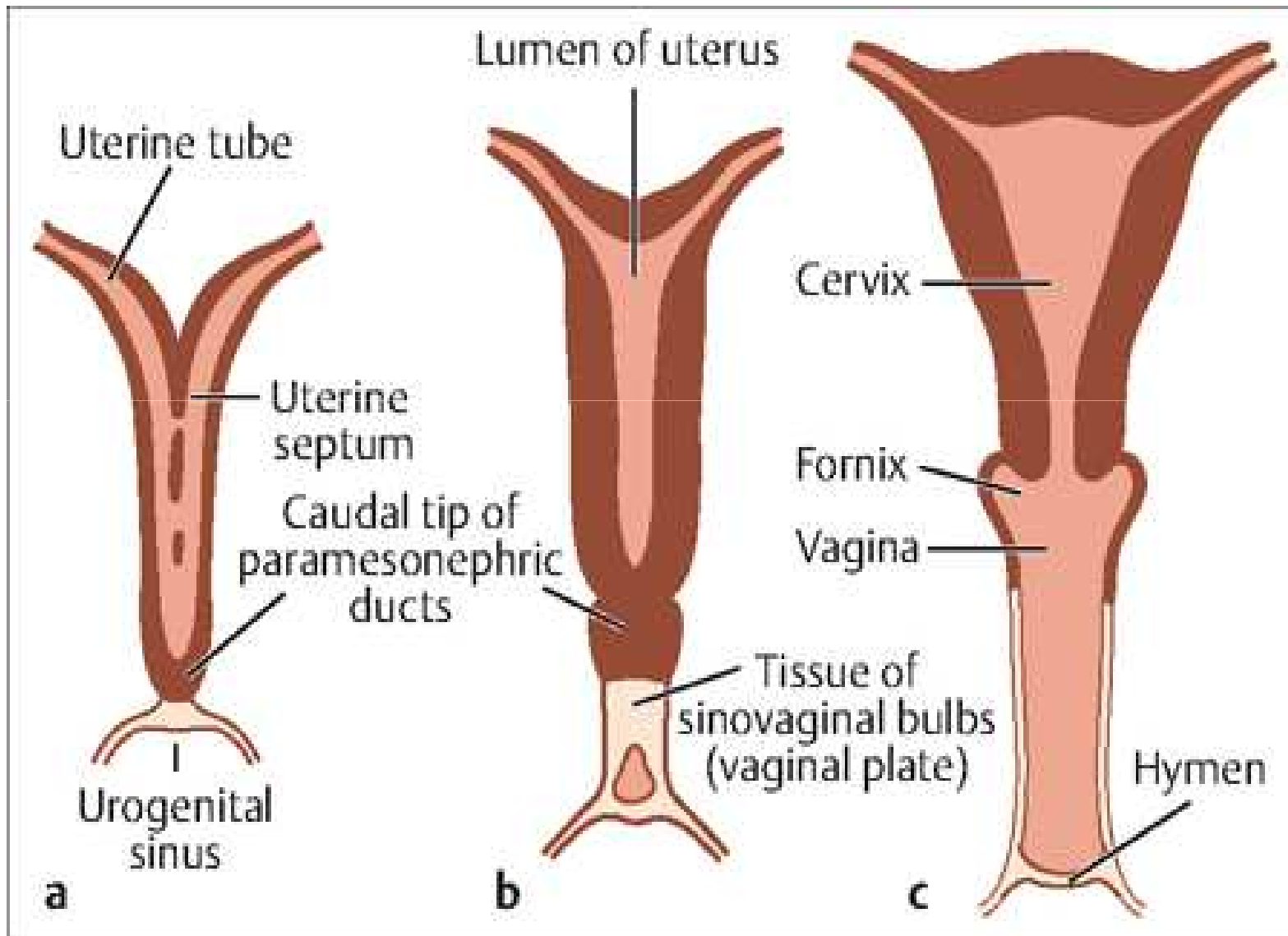
Testicular atrophy



Mullerian abnormality



Mullerian abnormality



Types of anomalies

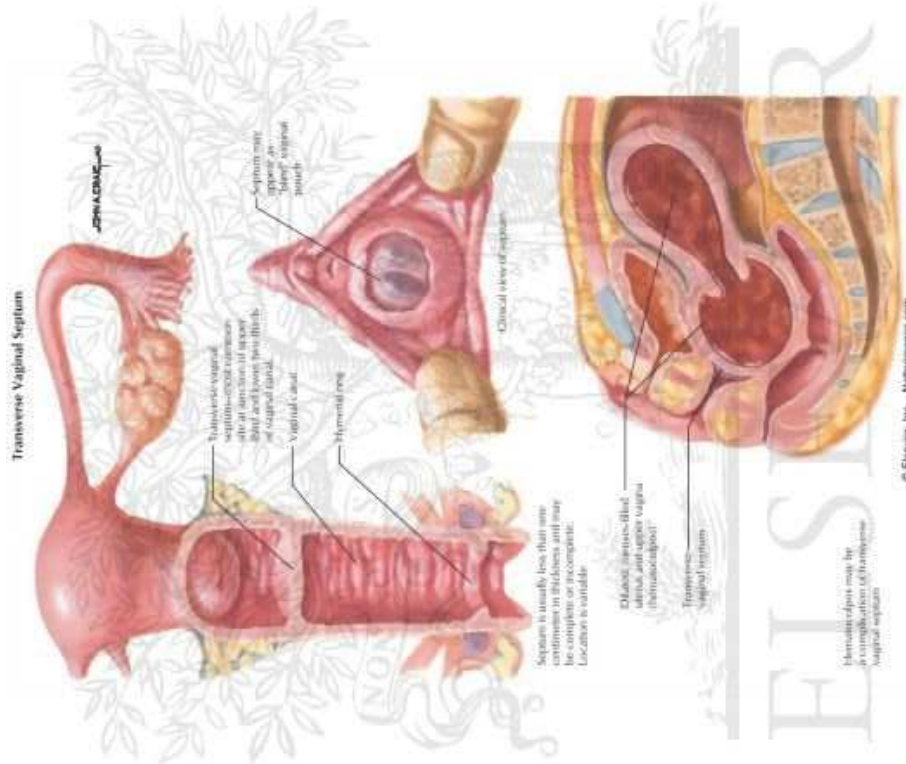
- Mullerian dysgenesis (unicornuate uterus)
- Mullerian agenesis (complete & incomplete)
- Failure of fusion which either transverse or longitudinal

Transverse fusion defect

- imperforated hymen (hymen is not of mullerian origin)
- vaginal septum

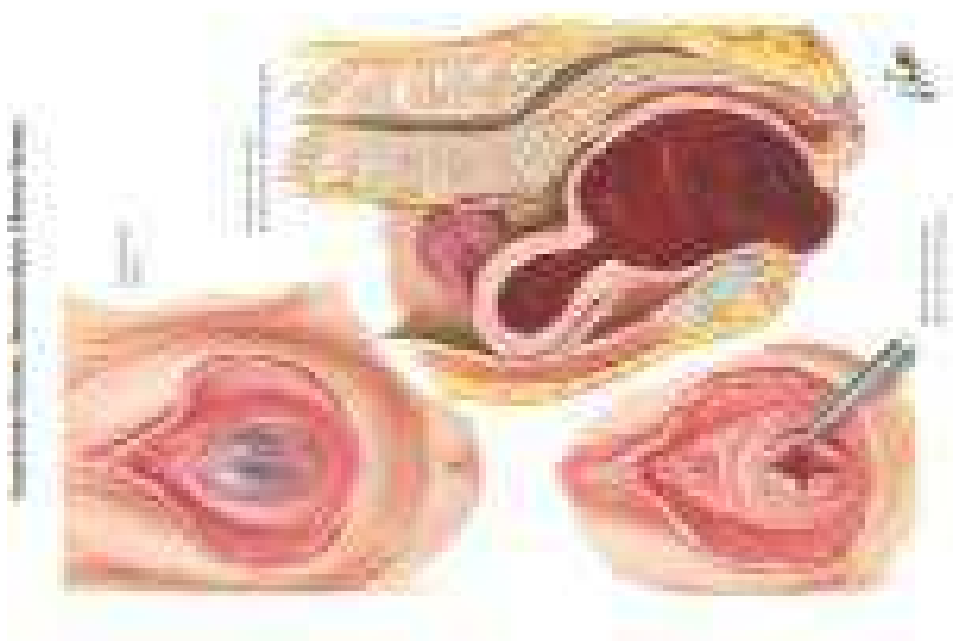
Longitudinal fusion defect

- uterine septum (complete & incomplete)
- duplication of uterus only
- Duplication of uterus and cervix
- longitudinal vaginal septum (complete & incomplete)

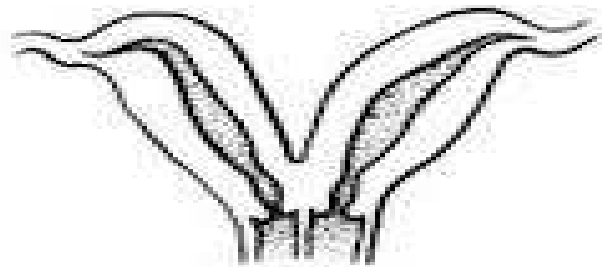


© Elsevier Inc. - Netterimages.com


© ELSEVIER, INC. - NETTERIMAGES.COM



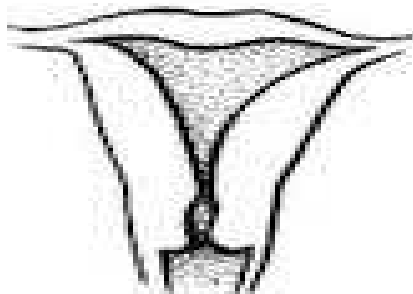
Mullerian anomalies



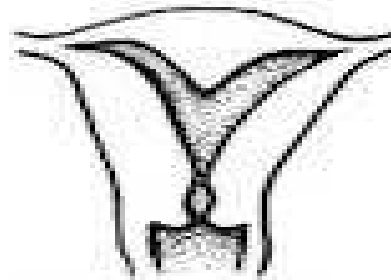
Didelphic



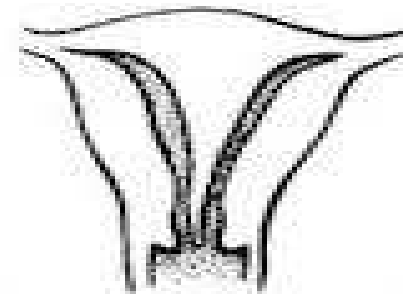
Unicornuate



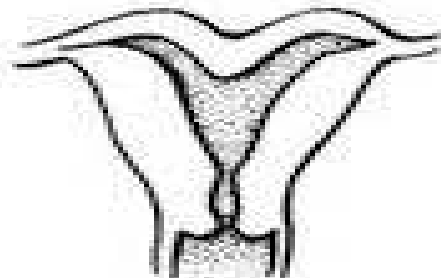
Arcuate



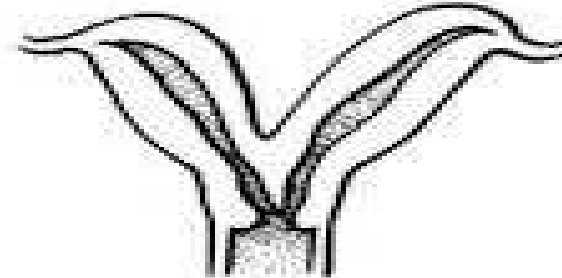
Septate (partial)



Septate (complete)



Bicornuate (partial)

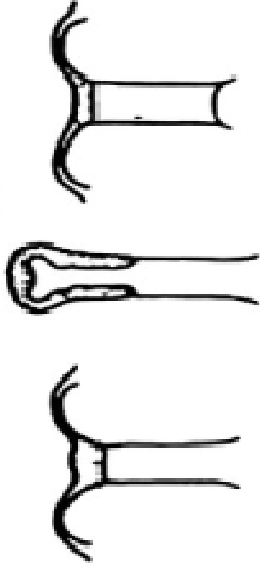


Bicornuate (complete)

I Hypoplasia/agenesis




(a) Vaginal (b) Cervical



(c) Fundal (d) Tubal (e) Combined

II Unicomuate



(a)

Communicating



(b) Non

Communicating




(c) No cavity

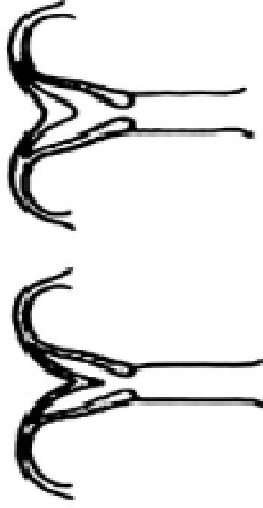


(d) No horn

III Didelphus

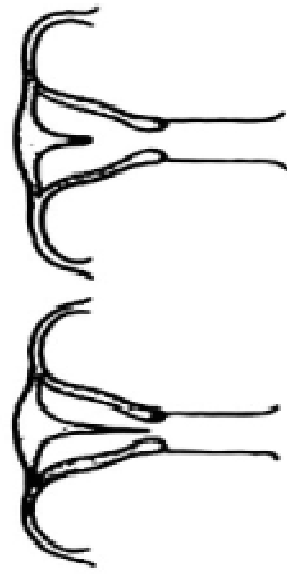


IV Bicomuate



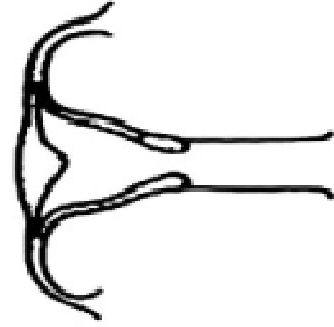
(a) Complete (b) Partial

V Septate

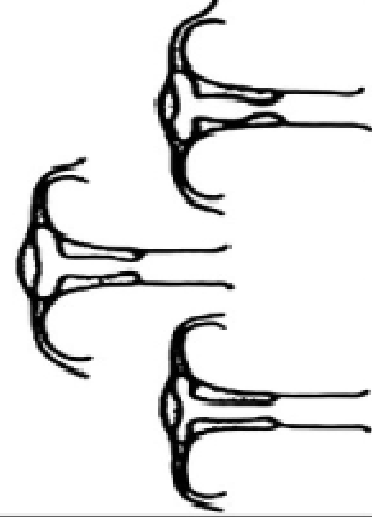


(a) Complete (b) Partial

VI Arcuate



VII DES drug related



Investigation

Imaging technique

Ultrasound

Hysterosalpingography

Saline sonography

vaginoscopic examination

Hysteroscopic examination

MRI

Presentation of mullerian anomalies

female with normal secondary sexual characters and normal karyotype

Agenesis

Primary amenorrhea

primary infertility

Transverse defect result in obstruction

Primary amenorrhea

Cryptomenorrhea

Longitudinal defect

asymptomatic

Menorrhagia

Dysmenorrhea

Pregnancy and mullerian anomalies

Depend on severity of defect

No effect

Recurrent pregnancy loss

Ectopic pregnancy

Abnormal placentation

Malpresentation

Preterm labour

Dystocia (abnormal labour)

Increased operative delivery

Postpartum hemorrhage

Treatment

No intervention in mild defect

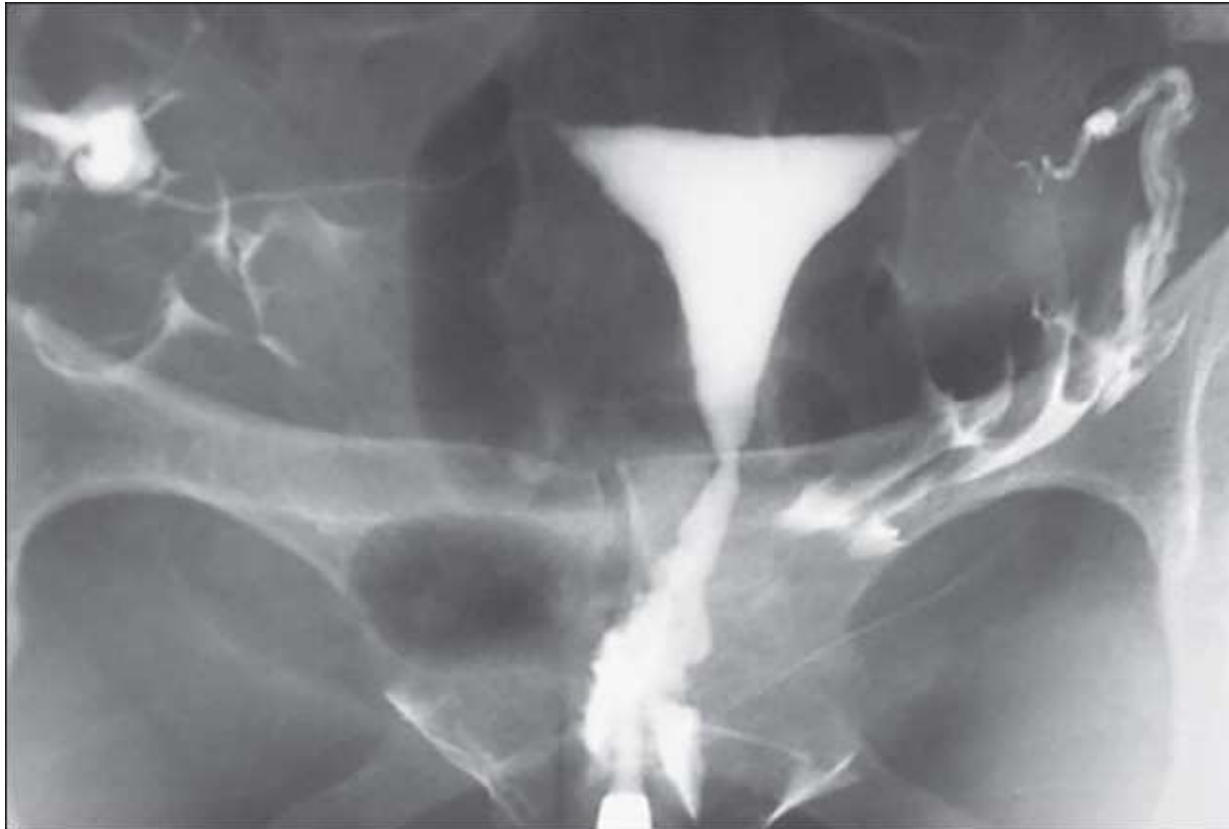Usually surgical

- hymenectomy

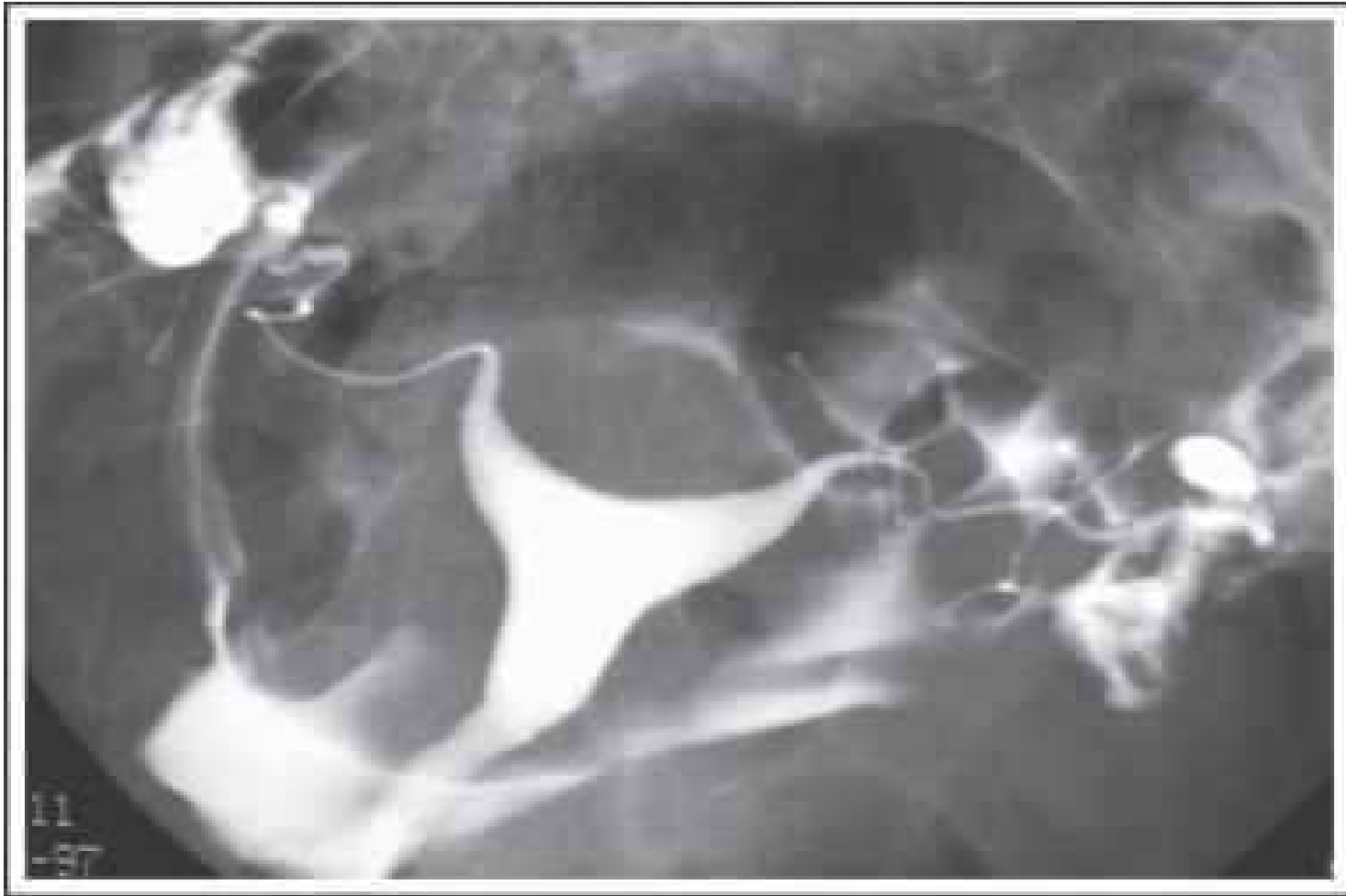
- vaginal and uterine septectomy

- Metroplasty for major defect

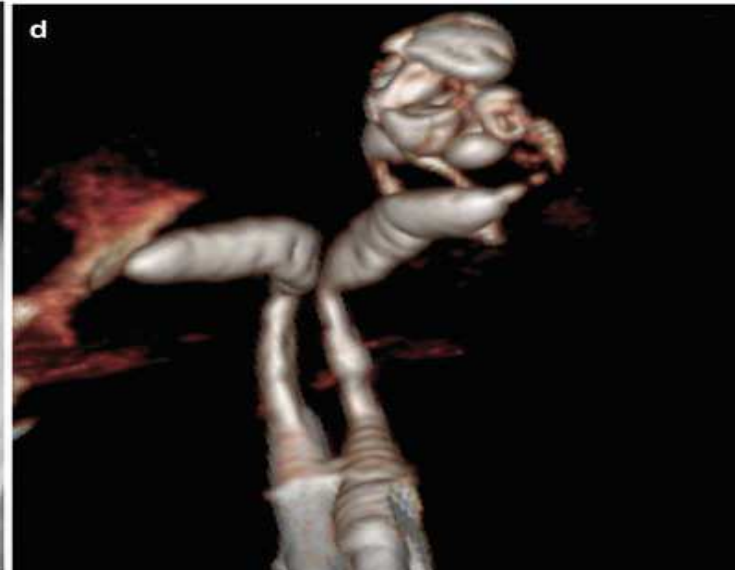
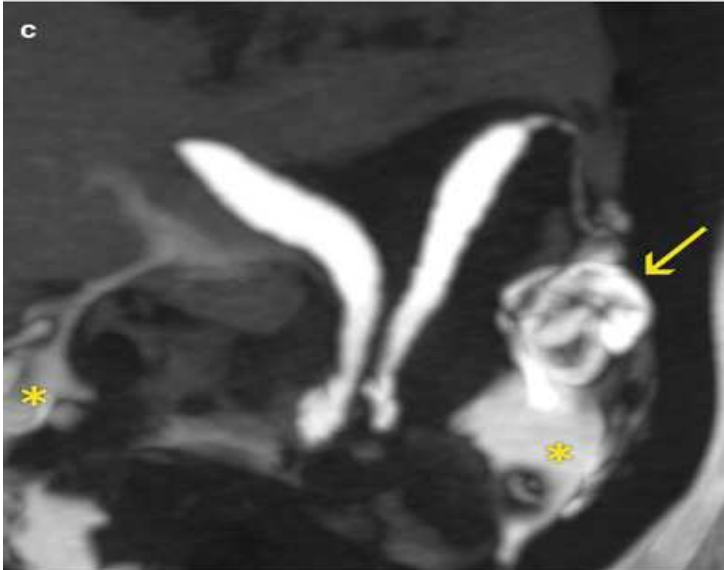
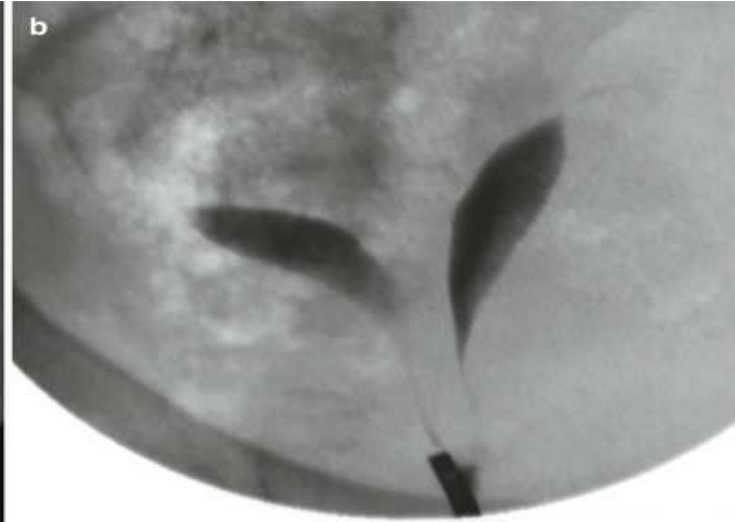
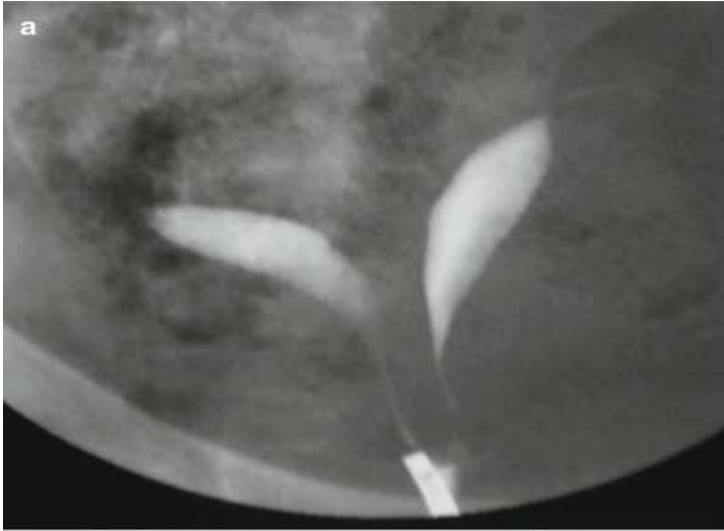
Normal HSG



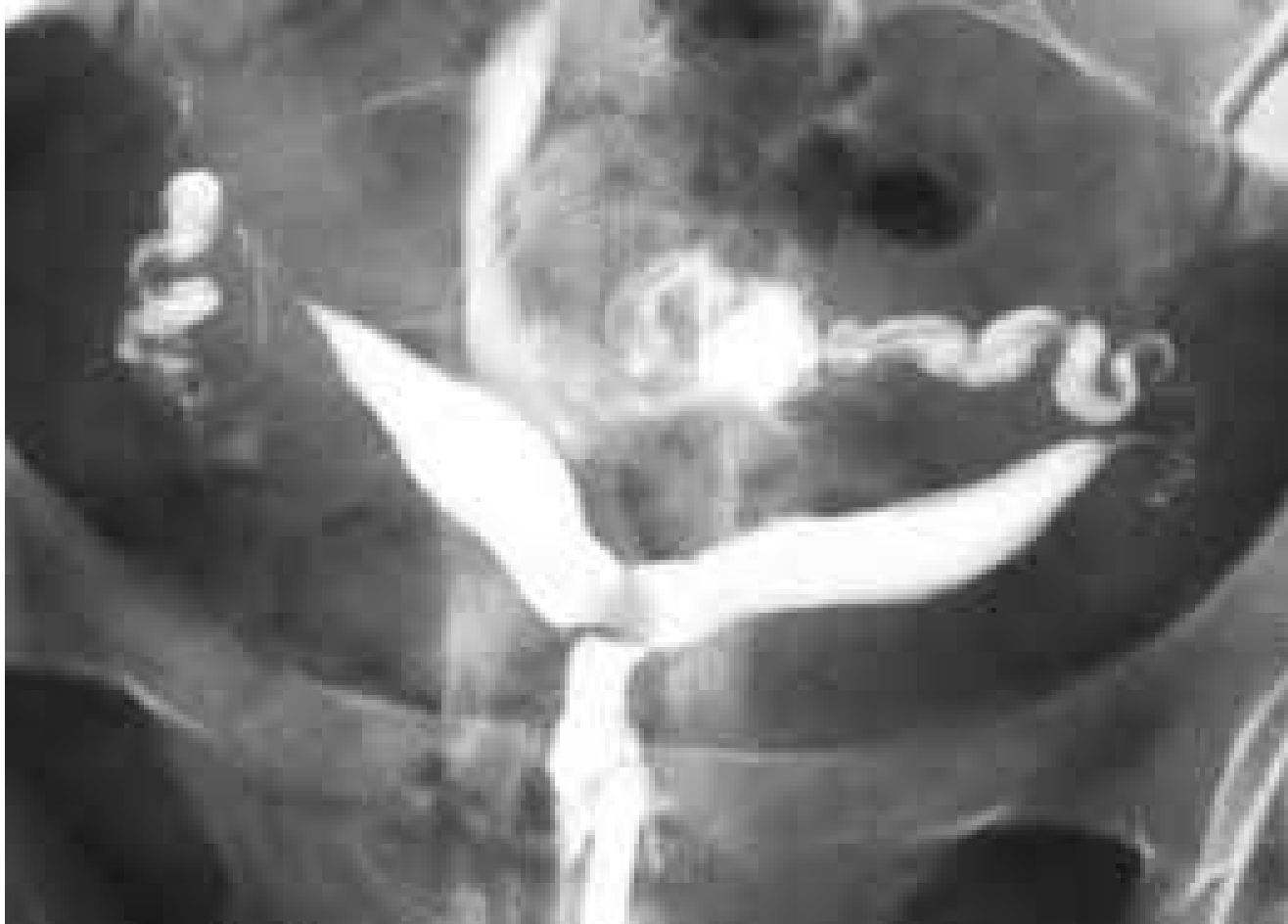Diagnosis ???



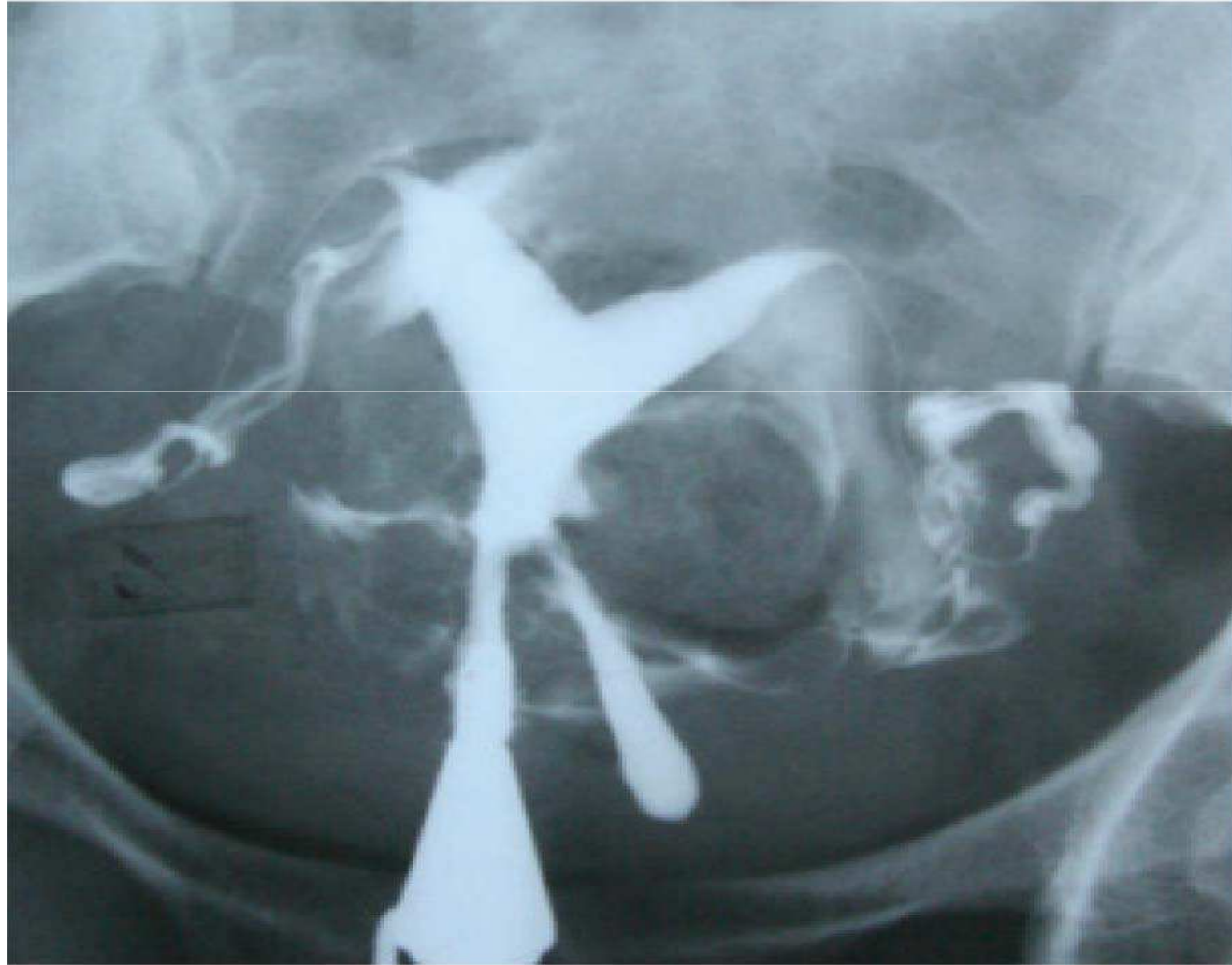Diagnosis ???



Diagnosis ???



Diagnosis ???



Thank you