

5- The normal electrocardiogram (ECG)

Introduction

Electrocardiography is a process of recording electrical activities of heart muscle at skin surface. The electrical current spreads into the tissues surrounding the heart, a small of these spread toward the surface of the body. Most the **electrocardiograph** machines amplify and record the electrical activity on a moving strip of paper. The record from this procedure is termed an **electrocardiogram**. Depolarization moving toward an active electrode produces a positive deflection, whereas moving in the opposite direction produces a negative deflection and when it is moving at right angle to lead no deflection. The magnitude of depolarizing wave is determined by mass of tissue. The horizontal axis of the ECG paper records time, , each 25 millimeters (5 large squares) in the horizontal direction is 1 second, and each 5-millimeters (5 small squares) represents 0.20 second. The 0.20-second intervals are then broken into five smaller intervals, each of which represents 0.04 second. The vertical axis records ECG amplitude (voltage). 10 of the small squares upward or downward in the standard electrocardiogram represent 1 millivolt, with positivity in the upward direction and negativity in the downward direction. **Figure-5-1 and 2.**

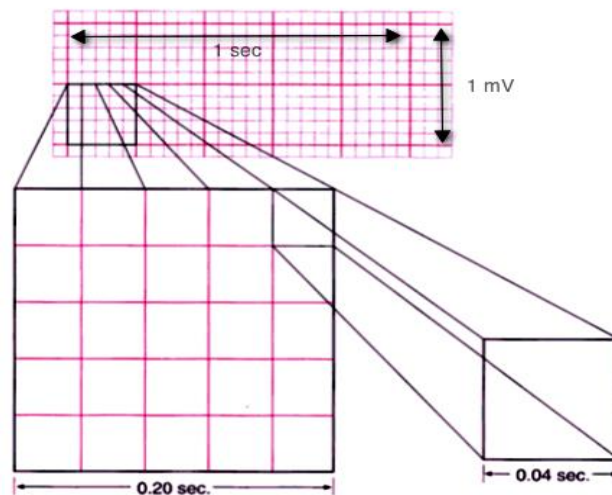


Figure 5-1:- ECG paper

The normal electrocardiogram of one cardiac cycle is composed of:

- 1- P wave** is produced by atrial depolarization.
- 2- PR segment** is isoelectrical, between end of P wave and beginning of QRS wave. It is due to delay in conduction of cardiac impulse through AV node.

3- PR or PQ interval is between the beginning of P wave and beginning of Q or R wave because Q wave is frequently absent (0.12 – 0.2 s).

4- QRS complex wave represents the ventricular depolarization (1 mv, not exceed 0.12 s). The atrial repolarization wave is usually obscured by much larger QRS complex wave.

5- ST segment is from end of S wave to beginning of T wave. It coincides with the plateau of ventricular action potential.

6- U wave is not constant finding, it is due to slow repolarization of papillary muscles.

7- QT interval which is measured from the onset of QRS complex to end of the T wave. (0.35 – 0.45 s). **Figure 5-2.**

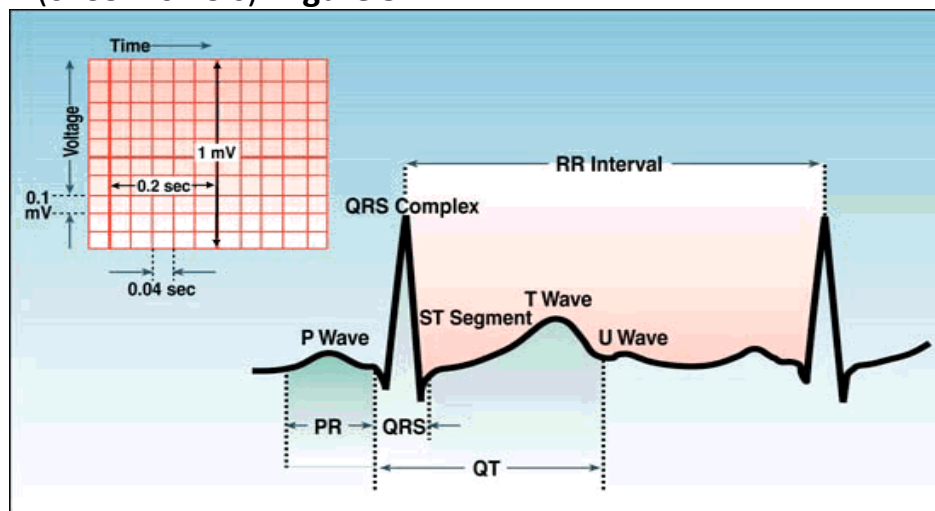


Figure 5-2 The normal electrocardiogram strip.

Types of leads:-

1- Bipolar limb leads: Bipolar leads were used before unipolar leads were developed.

The **standard limb leads** —leads I, II, and III

each record the differences in potential between two limbs.

- **LI** (between right arm and left arm).
- **LII** (between right arm and left leg).
- **LIII** (between left arm and left leg) (Figure 5-3).

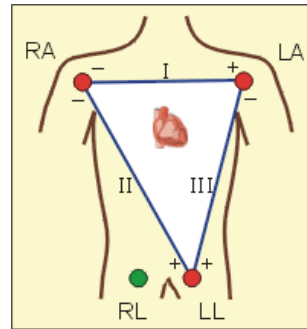


Figure 5-3 Bipolar limb leads.

2. Unipolar limb leads. three unipolar limb leads: VR (right arm), VL (left arm), and VF (left foot). **These Augmented limb leads**, designated by the letter a so they are written as (aVR, aVL, aVF) (figure 5-4).

3- Unipolar chest leads: There are six unipolar chest leads (precordial leads) designated V 1 –V 6 **Figure- 5-4 & 5.**

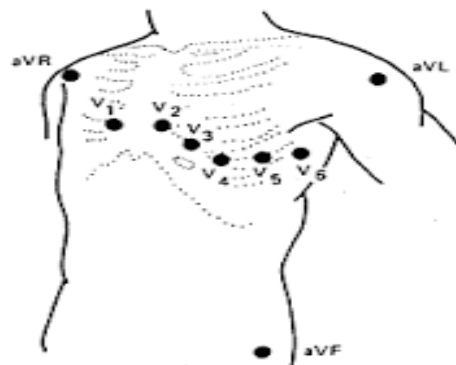


Figure 5-4 Unipolar limb leads & unipolar chest leads

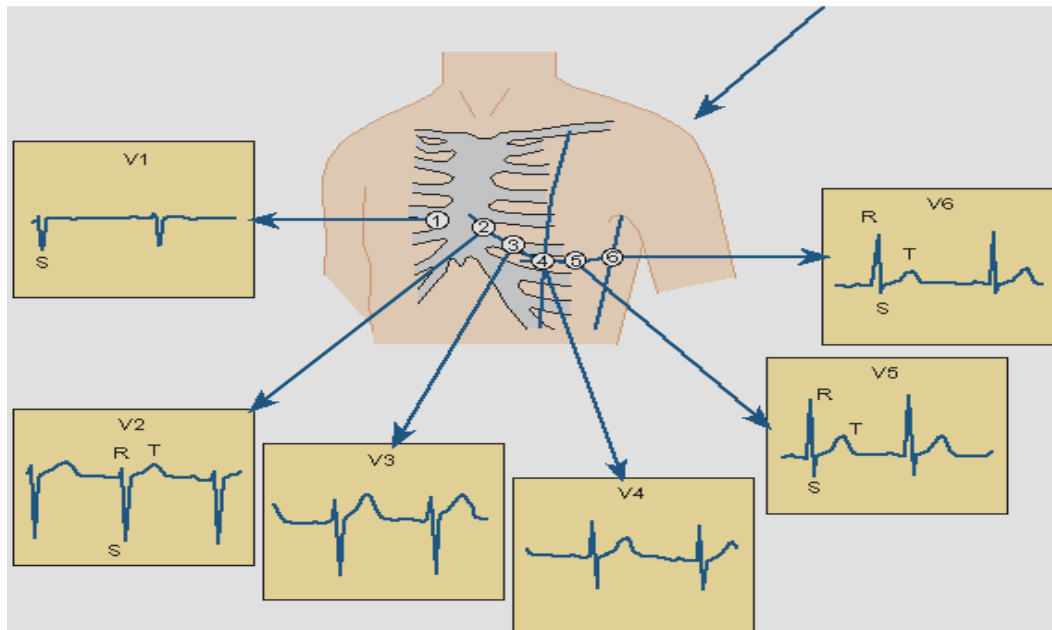


Figure 5-5 Sites of six unipolar chest leads (V1 –V6).

To determine sites of chest leads:

From the angle of Louis, move your fingers to the right and you will feel a gap between the ribs. This gap is the 2nd Intercostal space. From this position, run your fingers downward till you reach 4th intercostal space which is the position for V1. So sites of six chest leads are:

V1: right 4th intercostal space.

V2: Left 4th intercostal space.

V3: midway between V2 and V4.

V4: Left 5th intercostal space, at left mid clavicular line.

V5: Left 5th intercostal space, at left anterior axillary line.

V6: Left 5th intercostal space, at left mid-axillary line.

Normal electrocardiogram of 12 leads:-

1- In leads V1 and V2, the QRS of the normal heart are mainly negative because these chest leads are nearer the base of the heart than apex. No Q wave in these leads, with small R wave and large S wave. On other hand, the QRS complexes in leads V4, V5 and V6 are mainly positive because these leads are in the apex. Small Q wave in these leads, with large R wave and moderate S wave.

2- In the lead aVR, the P wave, QRS complex wave and T wave are inverted. While in aVL and aVF leads, they are positive.

3- In normal bipolar limb leads (I, II, III) showed one similar to another because they all record positive P wave, T wave and major portion of the QRS complex.

Figure 5-6

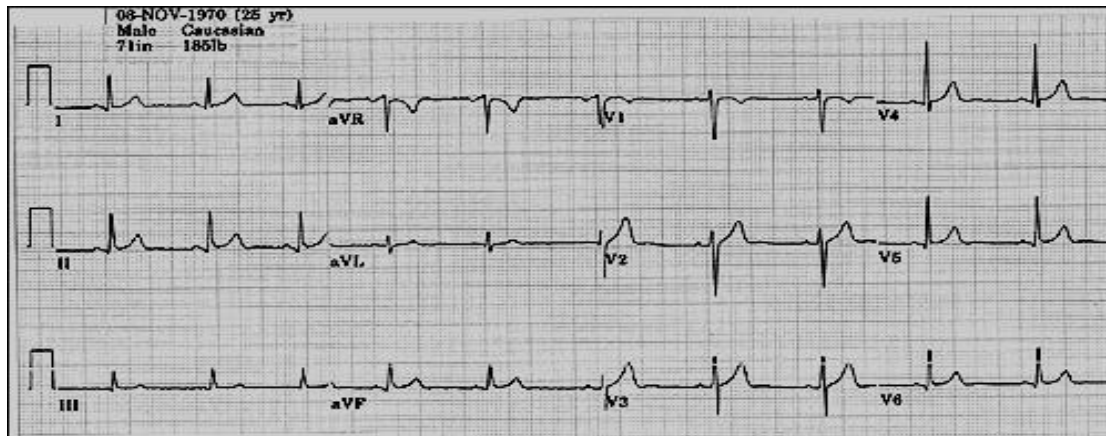


Figure 5-6: The normal electrocardiogram of 12 leads

Objective:-

To record the normal electrical potential of the heart muscle by electrocardiograph machine and how to analyze the ECG.

Material and instruments:-

- 1- Subject.
- 2- Electrocardiograph machine.

Method

- 1-The subject must be lie down and relax (prevent muscle contraction).
- 2-Connect up the four limb leads and six unipolar chest leads to correct sites.
- 3- Calibrate the voltage with the 1mv, vertically 1cm (2 large squares).
- 4- Calibrate the rate 25 mm/second.
- 5- Record the all 12 leads.
- 6- Record for each lead three or four complex waves.

Analysis of the ECG

1-Heart rate:

-When the rhythm is regular: The ECG paper passes 25 mm (25 small squares) at one second. One minute = 60 seconds. The duration of 25 small squares is equal to one second. The ECG paper passes $25 \times 60 = 1500$ small squares / minute. The heart rate is a number of heart cycles per minutes. So the heart rate = $1500 / \text{number of small squares between two consecutive R waves}$. or by counting the number of large squares between two consecutive R waves and dividing this into 300.

-When the rhythm is irregular as in atrial fibrillation, numbers of QRS complex are counted in 5 second in the strip multiplied by 12 to get the HR/minute.

2-Rhythm : Heart rhythm can be either regular or irregular .This can be determined by looking again at the R-R wave interval. If the R-R interval is inconsistent then the rhythm would be classed as irregular.

An irregular rhythm with no distinct p waves suggests atrial fibrillation. **Figure 5-7 & 8.**

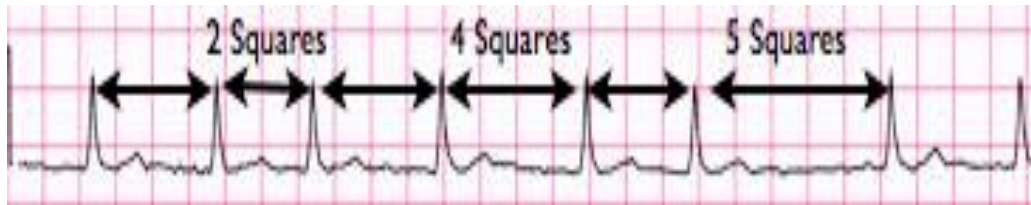

Figure 5-7

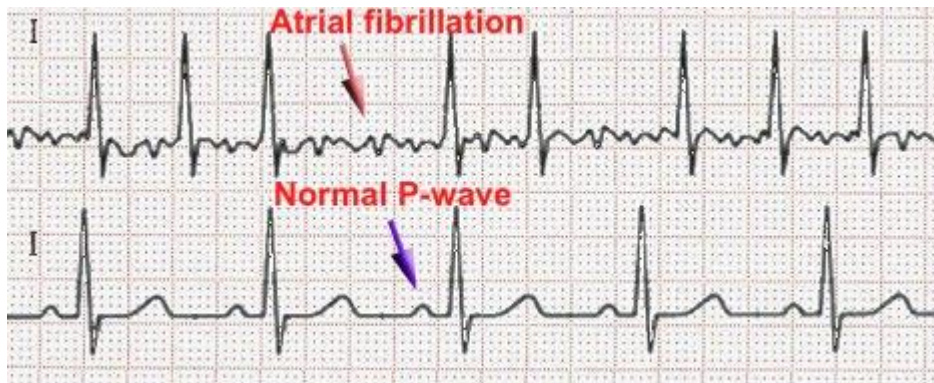


Figure 5-8

3-Electrical axis: Cardiac axis describes the overall direction of electrical spread within the heart . In a healthy individual the axis should spread from 11 o'clock to 5 o'clock, **figure 5-9.**

It is important to decide whether this axis is in normal direction or not.

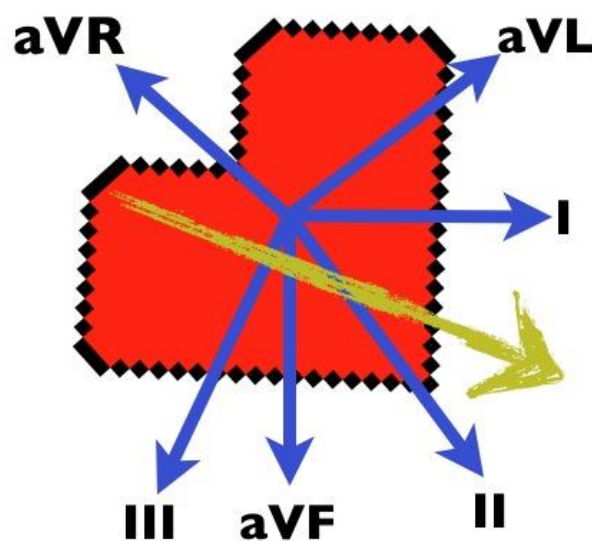


Figure 5-9 Normal direction of cardiac axis.

The direction of the axis can be derived more easily from QRS complex in lead I, lead II, and lead III.

-Right axis deviation: In right axis deviation Lead III has the most positive deflection (upward) as depolarization spreading towards it. Lead I should be negative (downward) because depolarization is spreading away from it. This is commonly seen in individuals with Right Ventricular Hypertrophy. **Figure 5-10**

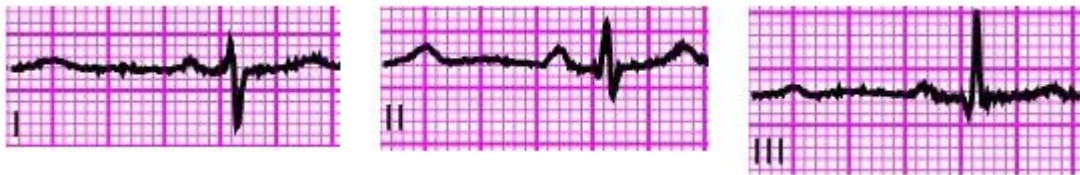

Figure 5-10 Right axis deviation.

-Left axis deviation : In left axis deviation Lead I has the most positive deflection & Leads II & III are negative. **Figure 5-11.**

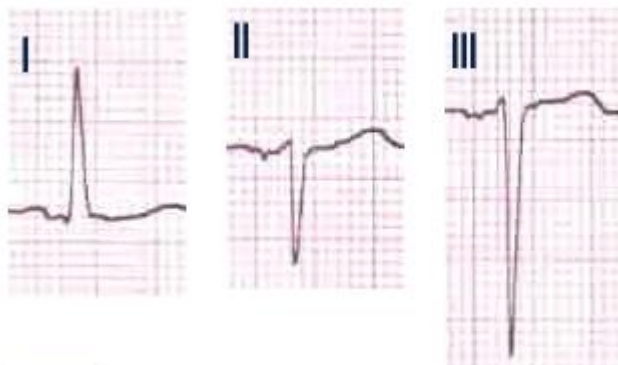


Figure 5-11 Left axis deviation.

4-Evaluation of P-wave morphology, QRS-morphology and T-wave morphology.

5-Evaluation of PR-interval, QT-interval and ST-segment morphology.